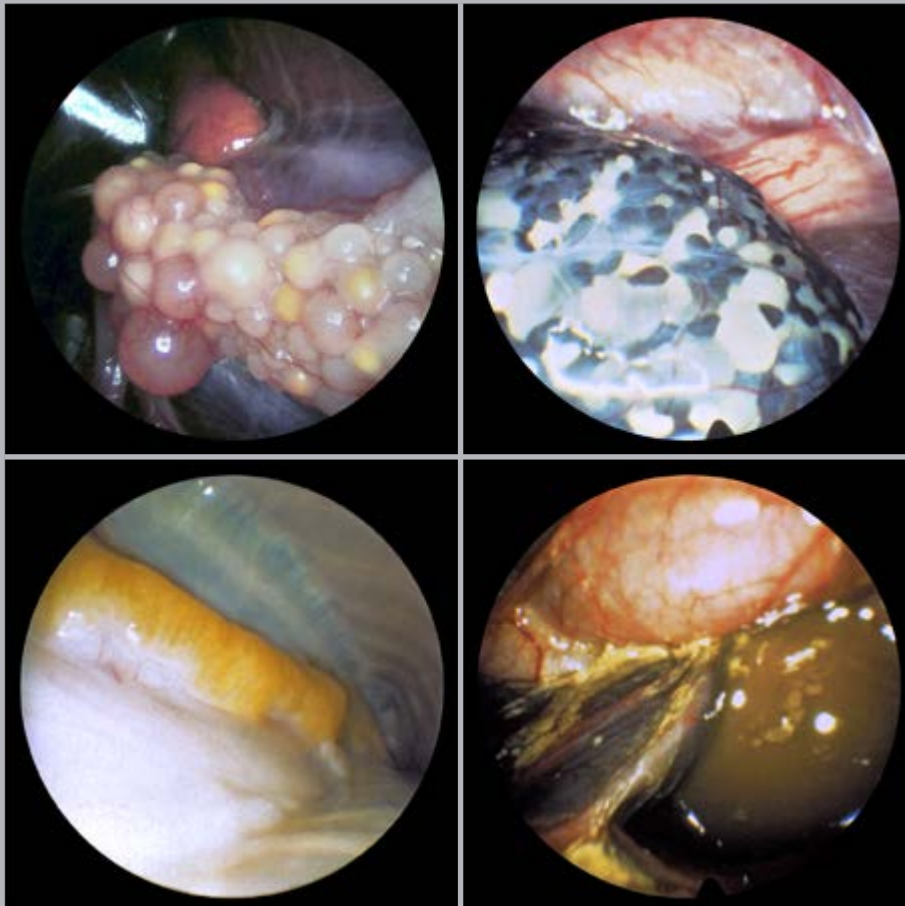


Endo:Press®

ENDOSCOPY IN BIRDS, REPTILES, AMPHIBIANS AND FISH



Michael J. MURRAY
Bernd SCHILDGER
Michael TAYLOR

Important notes:

Medical knowledge is ever changing. As new research and clinical experience broaden our knowledge, changes in treatment and therapy may be required. The authors and editors of the material herein have consulted sources believed to be reliable in their efforts to provide information that is complete and in accord with the standards accepted at the time of publication. However, in view of the possibility of human error by the authors, editors, or publisher, or changes in medical knowledge, neither the authors, editors, publisher, nor any other party who has been involved in the preparation of this booklet, warrants that the information contained herein is in every respect accurate or complete, and they are not responsible for any errors or omissions or for the results obtained from use of such information. The information contained within this booklet is intended for use by doctors and other health care professionals. This material is not intended for use as a basis for treatment decisions, and is not a substitute for professional consultation and/or use of peer-reviewed medical literature.

Some of the product names, patents, and registered designs referred to in this booklet are in fact registered trademarks or proprietary names even though specific reference to this fact is not always made in the text. Therefore, the appearance of a name without designation as proprietary is not to be construed as a representation by the publisher that it is in the public domain.

The use of this booklet as well as any implementation of the information contained within explicitly takes place at the reader's own risk. No liability shall be accepted and no guarantee is given for the work neither from the publisher or the editor nor from the author or any other party who has been involved in the preparation of this work. This particularly applies to the content, the timeliness, the correctness, the completeness as well as to the quality. Printing errors and omissions cannot be completely excluded. The publisher as well as the author or other copyright holders of this work disclaim any liability, particularly for any damages arising out of or associated with the use of the medical procedures mentioned within this booklet.

Any legal claims or claims for damages are excluded.

In case any references are made in this booklet to any 3rd party publication(s) or links to any 3rd party websites are mentioned, it is made clear that neither the publisher nor the author or other copyright holders of this booklet endorse in any way the content of said publication(s) and/or web sites referred to or linked from this booklet and do not assume any form of liability for any factual inaccuracies or breaches of law which may occur therein. Thus, no liability shall be accepted for content within the 3rd party publication(s) or 3rd party websites and no guarantee is given for any other work or any other websites at all.

Endoscopy in Birds, Reptiles, Amphibians and Fish

Michael J. Murray, DVM, U.S.A.
Bernd Schildger, DVM, Switzerland
Michael Taylor, DVM, Canada

Correspondence address of the author:

Michael J. Murray, DVM
 Avian and Exotic Clinic of Monterey Peninsula
 2 Harris Court Suite A-1
 Monterey, CA 93940
 Phone: +1 831-647-11 47
 Fax: +1 831-373-44 82

Bernd Schildger, DVM
 Tierpark Dählhölzli, Director
 Tierparkweg 1
 CH-3005 Bern, Switzerland
 Phone: +41 313571515
 Fax: +41 313571510

Michael Taylor, DVM
 Service Chief, Avian / Exotic Animal Medicine
 University of Guelph, Canada
 Veterinary Teaching Hospital
 Guelph, Ontario,
 N2G 2W1, Canada
 Phone: +1 519-8244120
 Fax: +1 519-7631276

All rights reserved.

1st edition 1999

© 2015 Endo:Press® GmbH
 P.O. Box, 78503 Tuttlingen, Germany
 Phone: +49 (0) 74 61/1 45 90
 Fax: +49 (0) 74 61/708-529
 E-Mail: Endopress@t-online.de

No part of this publication may be translated, reprinted or reproduced, transmitted in any form or by any means, electronic or mechanical, now known or hereafter invented, including photocopying and recording, or utilized in any information storage or retrieval system without the prior written permission of the copyright holder.

Editions in languages other than English and German are in preparation. For up-to-date information, please contact Endo:Press® GmbH at the address shown above.

Design and Composing:

Endo:Press® GmbH, Germany

Printing and Binding:

Straub Druck + Medien AG
 Max-Planck-Straße 17, 78713 Schramberg, Germany

06.15-03

ISBN 978-3-89756-851-8

Contents

1.0	Endoscopy in Birds	7	2.0	Endoscopy in Reptiles and Amphibians	31
1.1	Introduction	7	2.1	Introduction	31
1.2	Anesthesia	8	2.2	Anatomy	32
1.3	Anatomy	8	2.3	Indications	34
1.4	Indications	9	2.4	Anesthesia	34
1.5	Endoscopic Technique	9	2.5	Endoscopic Techniques	36
1.5.1	Examination of the Major Air Sacs and Coelom	9	2.5.1	Endoscopic Examination of the Pleuroperitoneal Cavity	36
1.5.2	Endodocumentation	10	2.5.2	Non Invasive Endoscopic Techniques	38
1.5.3	Non Invasive Endoscopy in Birds	11	2.6	Endoscopic Examination of the Pleuroperitoneal Cavity	40
1.5.3.1	Oropharynx	11	2.6.1	The pleuroperitoneal cavity	40
1.5.3.2	Trachea	12	2.6.2	Heart	41
1.5.3.3	Esophagus and Ingluvies	12	2.6.3	Lungs	42
1.5.3.4	Proventriculus, Ventriculus	13	2.6.4	Liver	44
1.6.1	Major Air Sacs and Coelom	14	2.6.5	Spleen	46
1.6.2	Lungs	16	2.6.6	Stomach and Intestines	47
1.6.3	Liver	17	2.6.7	Gonads	48
1.6.4	Heart and Pericardial Sac	18	2.6.8	Kidneys	50
1.6.5	Spleen	19	2.6.9	Bladder	52
1.6.6	Gastrointestinal Tract	20	2.6.10	Fat Bodies	53
1.6.7	Kidney	21	2.7	Non Invasive Endoscopy in Reptiles	54
1.6.8	Gonads	22	2.7.1	Tracheoscopy, Pneumonocopy	54
1.6.9	Ureters	24	2.7.2	Oesophagoscopy, Gastroscopy	54
1.6.10	Adrenal Glands	25	2.8	Endoscopy in Amphibians	55
1.7	Non Invasive Endoscopy in Birds	26	2.9	Literature	56
1.7.1	Oral Cavity	26	3.0	Endoscopy in Fish	59
1.7.2	Trachea	27	3.1	Introduction	59
1.7.3	Esophagus, Ingluvies, Proventriculus and Ventriculus	27	3.2	Anatomy	59
1.8	Literature	28	3.3	Indications	60
			3.4	Anesthesia	61
			3.5	Endoscopic Technique	63
			3.6	Samples of Endoscopic Features of Fish	67
			3.7	Literature	75
				Acknowledgements	75

**Recommended Endoscopes and Instruments
Video Documentation Systems and
Accessories for Endoscopy in Birds,
Reptiles, Amphibians and Fish 77**

Extracts from the following catalog:

VETERINARY ENDOSCOPY

– SMALL ANIMALS –

including section:

TELEPRESENCE – IMAGING SYSTEMS

Accessories for Illumination, Documentation
and Data Storage

ENDOSCOPY IN BIRDS



**Michael TAYLOR, DVM,
Service Chief,
Avian and Exotic Animal Medicine,
Veterinary Teaching Hospital,
University of Guelph, Ontario, Canada**

Endoscopy in Birds

Michael TAYLOR, DVM
Service Chief, Avian / Exotic Animal Medicine
University of Guelph, Canada
Veterinary Teaching Hospital
Guelph, Ontario,
N2G 2W1, Canada
Phone: +1-519-824 4120
Fax: +1-519-763 1276
e-mail: m.taylor@ovcnet.uoguelph.ca

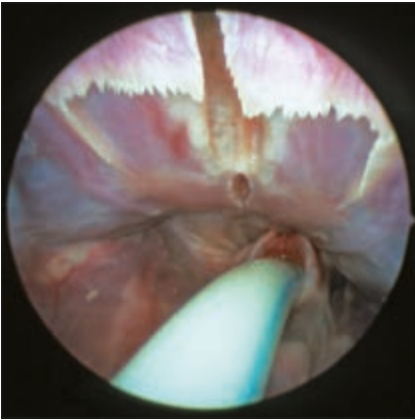
1.0 Endoscopy in Birds

1.1 Introduction

Fine diameter rigid endoscopes have been used for diagnostic purposes in birds since the late 1970's. During the decade of the 1980's this technology began to be employed with greater vigour by veterinarians in zoological and private practice. The value of a minimally traumatic procedure that allowed excellent visualization of internal structures even in very small patients soon became evident to many practitioners. Enhanced diagnostic sampling procedures were slower to develop. Avian medicine has seen spectacular growth in its knowledge base over the past fifteen years.

Rigid endoscopes were first employed in birds to visualize the gonads for purposes of sex identification in those species where external characteristics were difficult or impossible to rely upon. As private and public captive breeding programs began to flourish the need for reliable sex identification services drove the early clinical applications of endoscopic technology (HARRISON 1978, MACDONALD 1982 and JONES 1984). The superior resolution and light transmission characteristics of even the earliest rod lens endoscopes made them far superior to other optical systems for avian applications. A number of pioneering avian veterinarians soon realized that endoscopy offered far more than gonad identification capabilities. The unique anatomy of the avian respiratory system allowed relatively easy access to many organ systems. SATTERFIELD 1981 and KOLLIAS 1984 for example, described diagnostic uses of endoscopy that moved beyond organ visualization. Secondary hand instruments could be guided into the viewing field to collect biopsies or retrieve materials. Endoscopic collection of hepatic and renal biopsies allowed precise targeting of lesions with minimal patient trauma. LUMEIJ 1987 provided the first comprehensive overview of endoscopic access points for the bird, using the pigeon as a model. He was also the first to suggest the use of some method whereby hand instruments could be manipulated in concert with the endoscope.

A new endoscope and sheath system for avian use was developed in 1992 by the author (TAYLOR 1993). The sheath design allowed a variety of hand instruments to be guided to the tip of the endoscope through an instrument channel increasing operator ease and preventing iatrogenic trauma. (14.5 F. sheath 67065 CC and 2.7 mm endoscope 64018 BS, KARL STORZ Veterinary Endoscopy, Goleta, CA). The author first described an anatomic approach to better understand the most applicable access points for avian endoscopy in a comprehensive review (TAYLOR 1994).



1 Oropharynx.

Great horned owl (*Bubo virginianus*).
Endotracheal tube in place for gas anesthesia.

1.2 Anesthesia

Isoflurane gas anesthesia has become the standard for avian anesthesia since its introduction to the field in the mid 1980's. A number of parenteral agents, either singly or in combination, have been used such as ketamine, xylazine, diazepam, midazolam and propofol. In the author's opinion, none of these agents has proven to be as safe or consistently effective as isoflurane for endoscopic procedures. Birds are readily intubated by placing a soft, uncuffed endotracheal tube into the unencumbered glottis (**Fig. 1**). Remember that in most species the tracheal rings are complete.

1.3 Anatomy

The unique anatomy of the avian respiratory system facilitates endoscopic examination. The lungs are fixed to the dorsolateral ribs and do not change significantly in volume during the respiratory cycle. The air sacs of the bird arise from a variety of ostia in the lung and extensively invaginate the coelom (TAYLOR 1994). They provide access to most internal organs without the need for secondary insufflation. The caudal thoracic air sacs are the key entry points to the avian air sac system. The cranial thoracic and abdominal air sacs can be easily accessed from a single entry point into the caudal thoracic sacs via the lateral thoracic wall (**Fig. 2**). This permits inspection of most of the respective right or left hemicoelom. The peritoneum is partitioned by the invaginations of the air sacs. The liver is surrounded by the right and left ventral and dorsal hepatic peritoneal cavities. The rest of the abdominal viscera are suspended within the midline intestinal peritoneal cavity as they would be in the typical mammal.



2 Primary entry site for avian coeleoscopy.

Green winged macaw (*Ara chloroptera*) positioned in right lateral recumbency with the left leg positioned cranially.

1.4 Indications

Table 1: Indications for Endoscopic Examination

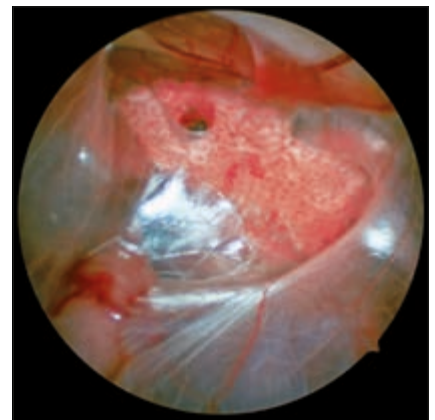Acute/Chronic	<ul style="list-style-type: none"> • Dyspnea • Sneezing
Ingluvitis	<ul style="list-style-type: none"> • Crop Burns or Trauma
Abnormal radiographic findings (plain or contrast) eg. air sacs	<ul style="list-style-type: none"> • Lung • Organomegaly • Gastrointestinal
Abnormal Biochemical Studies	<ul style="list-style-type: none"> • Elevated Uric Acid Levels (Kidney) • Elevated Bile Acids (Liver)
Persistent Leukocytosis	<ul style="list-style-type: none"> • Unexplained • Non-responsive to Treatment
Acute/Chronic	<ul style="list-style-type: none"> • Systemic Disease
Reproductive System	<ul style="list-style-type: none"> • Suspect Infertility
Polyuria, Polydipsia	

Follow-up examination to check on lesion resolution (Second look).

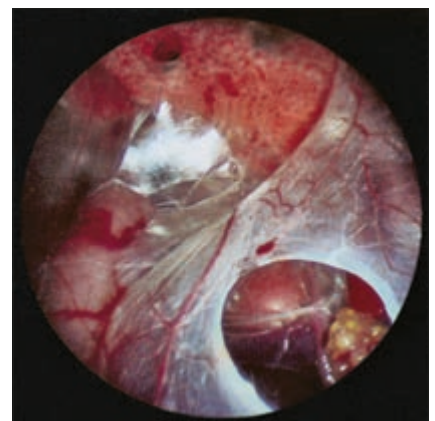
1.5 Endoscopic Technique

1.5.1 Examination of the Major Air Sacs and Coelom

An approach to the caudal thoracic air sacs has been developed that is based upon precise landmarks that are reproducible among a wide variety of species (TAYLOR 1994). The entry site is located by finding the point where the semimembranosus muscle (*m. flexor cruris medialis*) crosses the last rib. A blunt entry is recommended through the thin body wall just caudal to the last rib, beneath the reflected semimembranosus muscle. Except in individuals with moderately to markedly increased fat reserves, the landmarks are located easily and the entry site was found to be very reproducible in members from a wide variety of orders including psittaciformes, passeriformes, columbiformes, gruiformes, anseriformes, falconiformes and strigiformes. A major advantage in placing the leg forward is that the thin, lateral body wall can be more easily approached without the interference of the femoral musculature. This becomes particularly important in birds with heavily muscled upper thighs (eg. many psittaciformes). With this approach the endoscope enters the caudal thoracic air sac at or near its caudal border. Upon entering the left caudal thoracic air sac and looking cranially the lateral septal surface of the lung with its large ostium will be visible (**Fig. 3**). Running from approximately two to three o'clock is the transparent membrane formed by the confluent walls of the caudal thoracic air sac and the abdominal air sac. Passing through this wall would place the endoscope within the abdominal air sac (**Fig. 4**). At four to six o'clock is the ventrolateral border of the proventriculus and ventriculus. The lateral edge of the left lobe of the liver may be seen at seven to eight o'clock, draped upon the ventriculus. From nine to ten o'clock is another transparent membrane composed of the walls of the confluent caudal thoracic air sac and cranial thoracic air sacs. Passing through this membrane would place the tip of the endoscope in the cranial thoracic air sac.



3 Caudal thoracic air sac.
Red tailed hawk (*Buteo jamaicensis*).
Note the large ostium of the air sac visible on the lung surface. This is the standard entry point for most avian coeleoscopy.



4 Caudal thoracic air sac.
View through to abdominal air sac – red tailed hawk (*Buteo jamaicensis*).

1.5.2 Endodocumentation

The greatest practical advances in endodocumentation have occurred in the field of video imaging. Improvements in CCD chips allow greater sensitivity to low light levels combined with higher resolution when recorded on formats such as S-VHS and Hi8. Specialized endovideo cameras consist of a soakable hand piece that contains the CCD chip, a focusable lens and a quick connector. This unit is attached to the controller by a sealed cable. The controller, which contains all of the electronic circuitry for the camera, is placed out of the surgical field.

The sterilized camera may be used for the real time visualization of procedures and is preferred by some clinicians as an aid to performing certain manipulations. The procedure is observed on a monitor without the need for the surgeon to view the ocular. Portions or all of the examination can be recorded for later review. This can be a valuable research tool allowing comparison of many different examinations. Still images can be captured from recorded material using a video printer. These prints are adequate for the medical record or for client use.

High quality still photographs may only be obtained by the use of a specialized flash generator (eg. KARL STORZ TTL-Computer Flash Unit 600 C) with a single lens reflex camera fitted with a proprietary zoom lens. The photographs for this volume were exposed using this equipment.

Uses of Endovideo Documentation

- **Improved Ergonomics:** As an aid to performing instrumented procedures avoiding the need to keep head at eyepiece during instrument manipulation, more procedures can be performed with less fatigue.
- **For Case Documentation:** Particularly useful for showing relationships in space and time, medico-legal recording.
- **Teaching and Demonstration:** Superb education and marketing tool for clients, colleagues, staff.

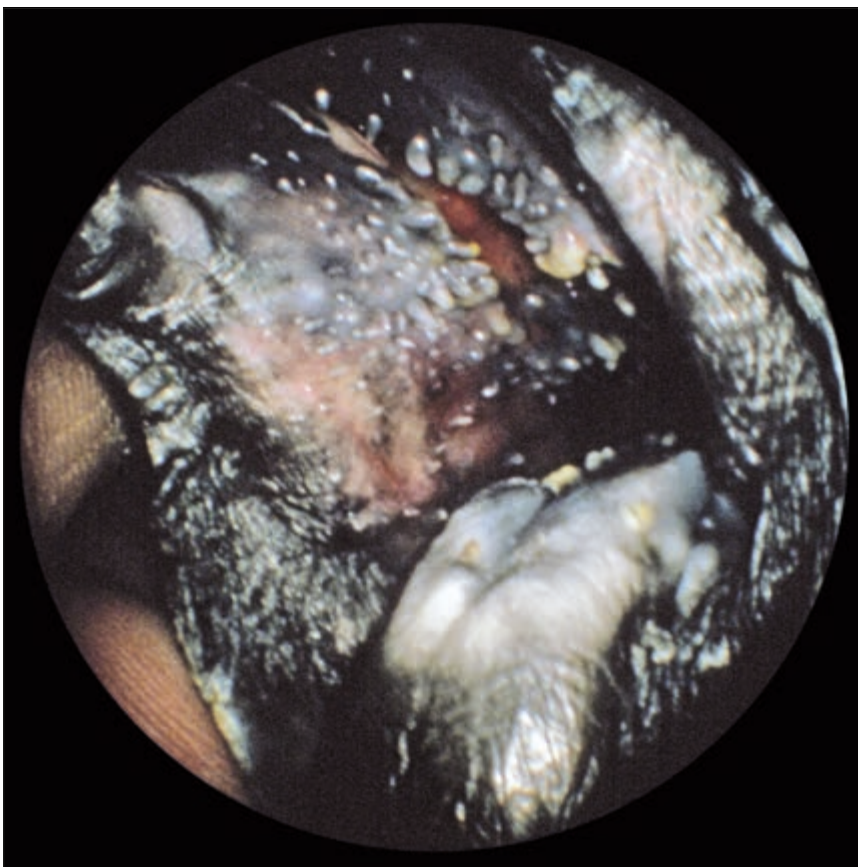
1.5.3 Non Invasive Endoscopy in Birds

1.5.3.1 Oropharynx

The oral cavity is easily approached in most avian species. The bill may be held open manually or a speculum can be employed. In species with strong mandibular musculature such as psittacines, it is recommended that the patient be anesthetized for most oral examinations. If manual restraint is used extra care must be taken to prevent damage to equipment.

The avian tongue may exhibit a number of adaptations for food prehension and manipulation. In many species it is a flat, triangular shaped organ with a relatively smooth epithelium. Psittaciforms have large, fleshy tongues ideally suited to food manipulation. They are the only order with intrinsic lingual muscles that allow a great variety of movement and flexibility. In many species, including parrots there are a group of mucus secreting salivary glands at the base of the tongue. Inspissation of keratinized debris due to squamous metaplasia will be seen in birds suffering from hypovitaminosis A (Fig. 5).

The laryngeal mound is visualized at the base of the tongue on the midline of the caudal floor of the oropharynx. The paired, fleshy laryngeal prominences open and close to form the conspicuous glottis. There is no epiglottis.



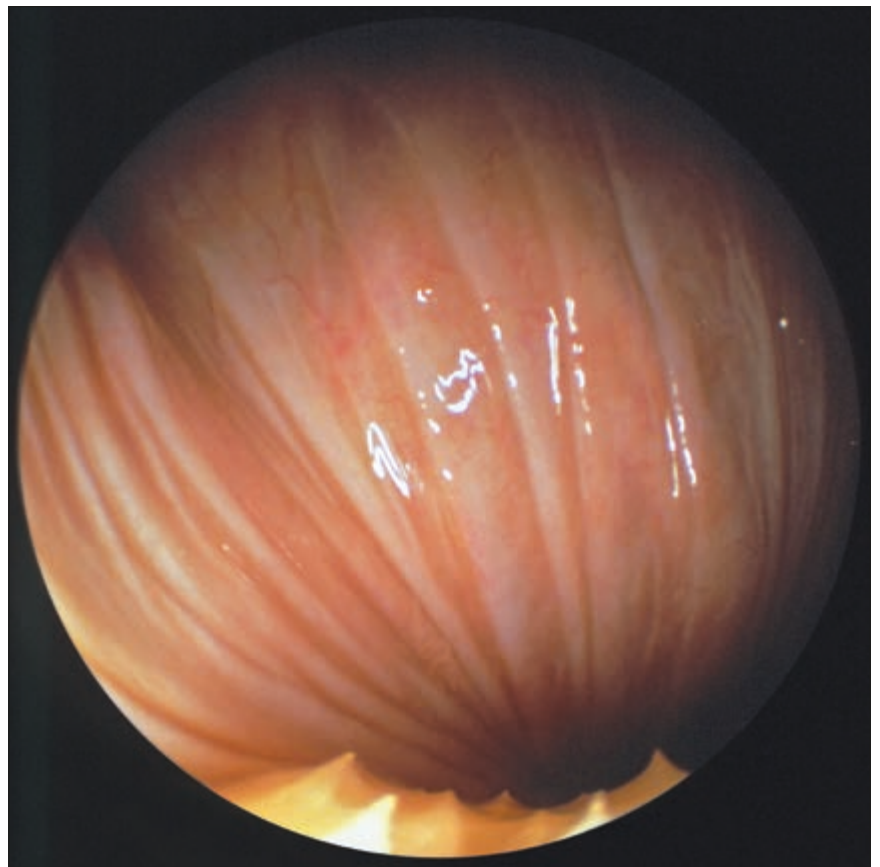
5 Chronic hypovitaminosis A.
Yellow naped amazon (*Amazona ochrocephala*).
Note the white, inspissated appearance of the salivary lingual glands.

1.5.3.2 Trachea

The trachea may be entered at the larynx by passing through the glottis of an anesthetized patient. The avian larynx does not contain vocal chords. Tracheal rings of the bird are usually calcified and are completely circular. The tracheal mucosa consists of a smooth stratified squamous epithelium. The syrinx is the site of sound production and is located where the trachea bifurcates into the primary bronchi. Tracheoscopy to the level of the syrinx is possible in medium to large birds using a 180 mm long 2.7 mm endoscope. Smaller patients may be examined with a 1.9 mm endoscope. Visualization can be improved by extending the neck.

1.5.3.3 Esophagus and Ingluvies

The esophagus is easily entered by passing caudally into the pharynx and over the laryngeal mound. The surface of the esophagus is thrown into a series of longitudinal folds that vary depending upon the types of food items that the species consumes. For example, the number and size of folds and the degree of distensibility are less in insectivores and seed eaters than in carnivores like hawks and owls (**Fig. 6**).



6 Oropharynx and esophageal folds.

Great horned owl (*Bubo virginianus*).

Birds that consume large boluses of food have noticeable folds of the esophageal mucosa.

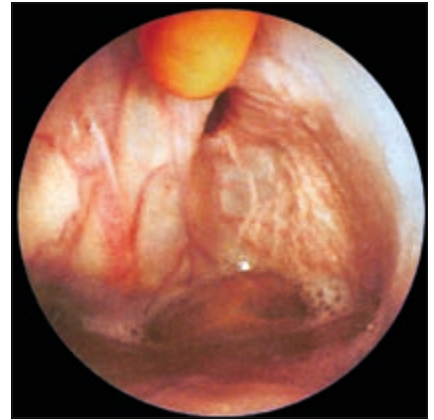The ingluvies can be examined with either a flexible or rigid endoscope after passing through the cervical portion of the esophagus. Insufflating the crop with air will help with visualization. Some pressure will need to be maintained around the proximal cervical esophagus to retain the infused air within the crop. It is also important to remember to fast patients undergoing elective ingluviotomy for several hours before the procedure to reduce the effects of retained food materials upon visualization.

1.5.3.4 Proventriculus, Ventriculus

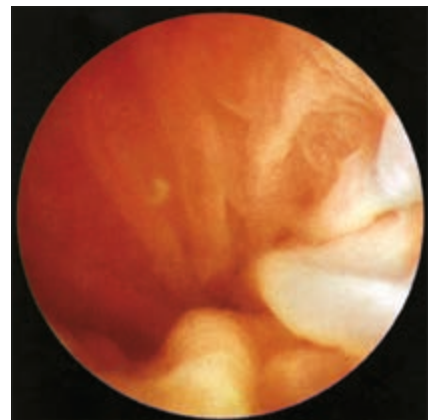
The proventriculus and the ventriculus may be examined using either flexible or rigid equipment. Due to the tremendous amount of work that has been done in mammalian gastroscopy, the clinician might assume that a flexible endoscope would be the first choice for this examination. The smallest practical flexible endoscopes with an instrument channel are pediatric bronchoscopes at 4.0 mm and 5.0 mm diameter. Smaller flexible instruments lack the optical quality of the KARL STORZ 2.7 mm endoscope and sheath.

I recommend a midline ingluviotomy to enter the thoracic esophagus using the endoscope and instrumented sheath. Once into the thoracic esophagus the pathway becomes a relatively straight one continuing into the proventriculus and then the ventriculus. Birds are anesthetized, intubated and placed in dorsal recumbency. A small skin incision was made over the middorsal portion of the crop and the crop wall is incised. The entrance to the thoracic esophagus is located on the the ventral, midline border of the crop (**Fig. 7, 8**) and the telescope and sheath are introduced. Whenever possible, patients are fasted for five to six hours to aid in emptying of the proventriculus. Care must be taken to avoid the passage of proventricular content into the trachea or choana. This can be prevented by inserting an absorbent gauze tampon into the cranial cervical esophagus and ensuring that the endotracheal tube is close fitting. The crop incision is closed using standard techniques.

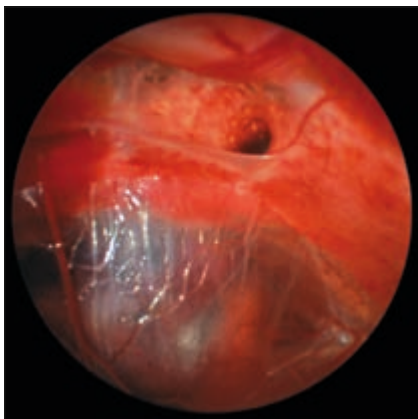
In species that are large enough and particularly those without a crop, a flexible pediatric bronchoscope or a larger human colonoscope may be used to enter the proventriculus and ventriculus. This is especially indicated in species with long necks such as Gruiformes and some Anseriformes.



7 Ingluvies and esophageal sphincter of the thoracic esophagus.
Moluccan Cockatoo (*Cacatua moluccensis*).
The esophageal sphincter is open due to the degree of insufflation present.



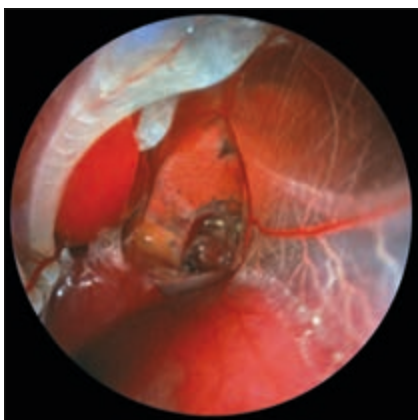8 Esophageal sphincter of the thoracic esophagus.
Green winged macaw (*Ara chloroptera*).



9 Caudal thoracic air sac.

Red breasted merganser
(*Mergus serrator*).

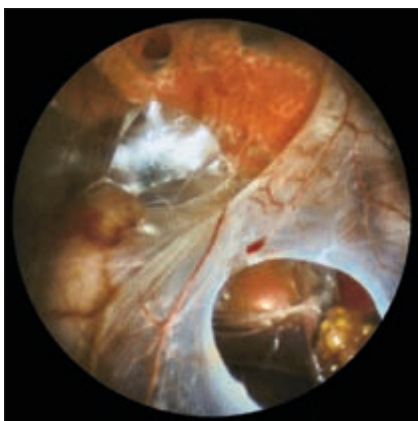Large ostium on the lung surface is visible. In many diving birds the caudal thoracic air sac is very large and the cranial thoracic air sac is relatively small.



10 Cranial thoracic air sac.

Orange winged amazon
(*Amazona amazonica*).

In this air sac the key landmark is the heart beating within the pericardial sac.

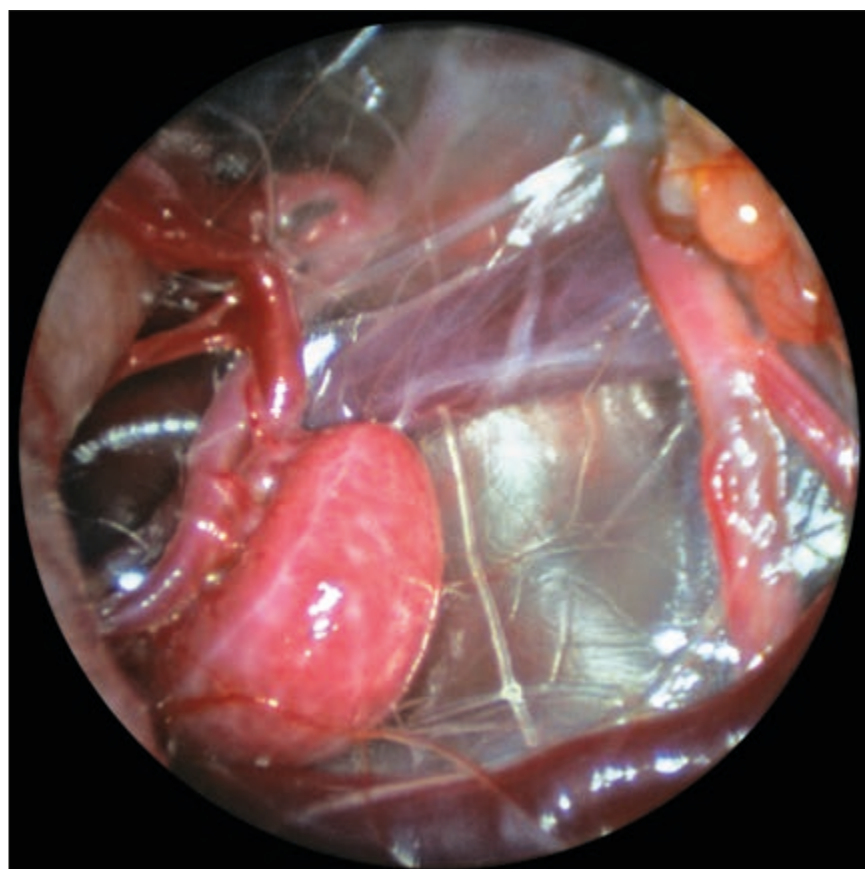

11 Caudal thoracic air sac.

View through to abdominal air sac –
Red tailed hawk (*Buteo jamaicensis*).
Note the puncture that has been made in the confluent walls of the caudal thoracic and abdominal air sacs.

1.6.1 Major Air Sacs and Coelom

The respective caudal thoracic air sac is the major entry point for avian air sac and coelomic endoscopy. From this site the cranial thoracic and abdominal air sacs can be entered. The left approach is usually the first site to be used because the greatest number of structures can be visualized from here.

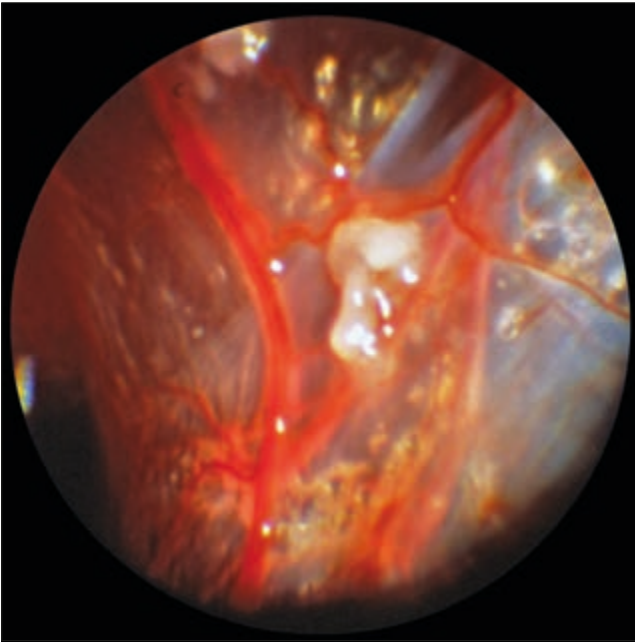


12 Abdominal air sac (left).

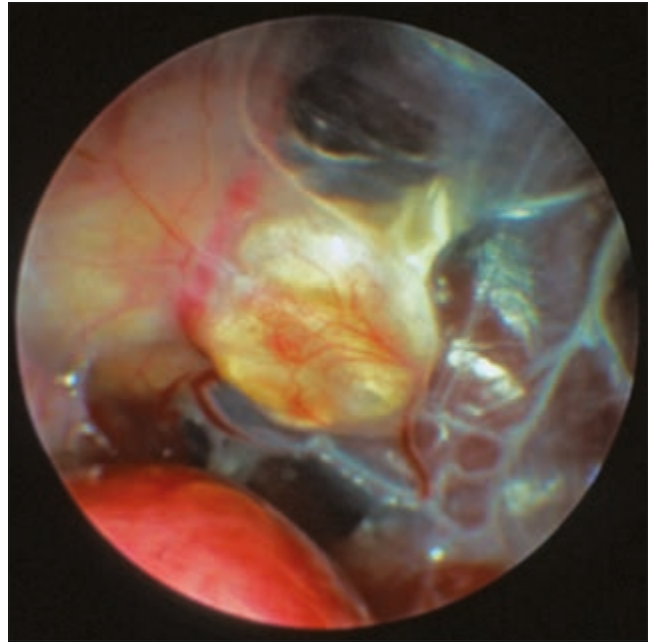
Red tailed hawk (*Buteo jamaicensis*).

The spleen and ovary are visible in this view of the cranial portion of the left abdominal air sac.

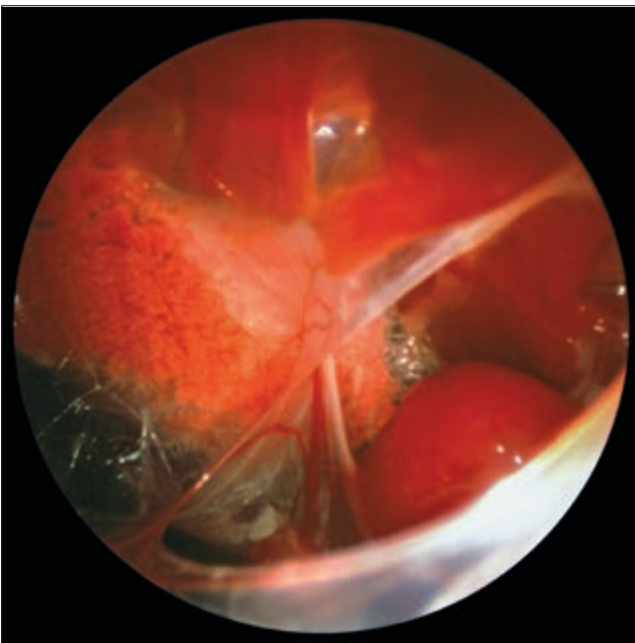▼ Pathological Alterations



13 Granulomatous airsacculitis.
Green winged macaw (*Ara chloroptera*).
Typical pattern seen with both inhaled and hematogenous air sac inflammation.

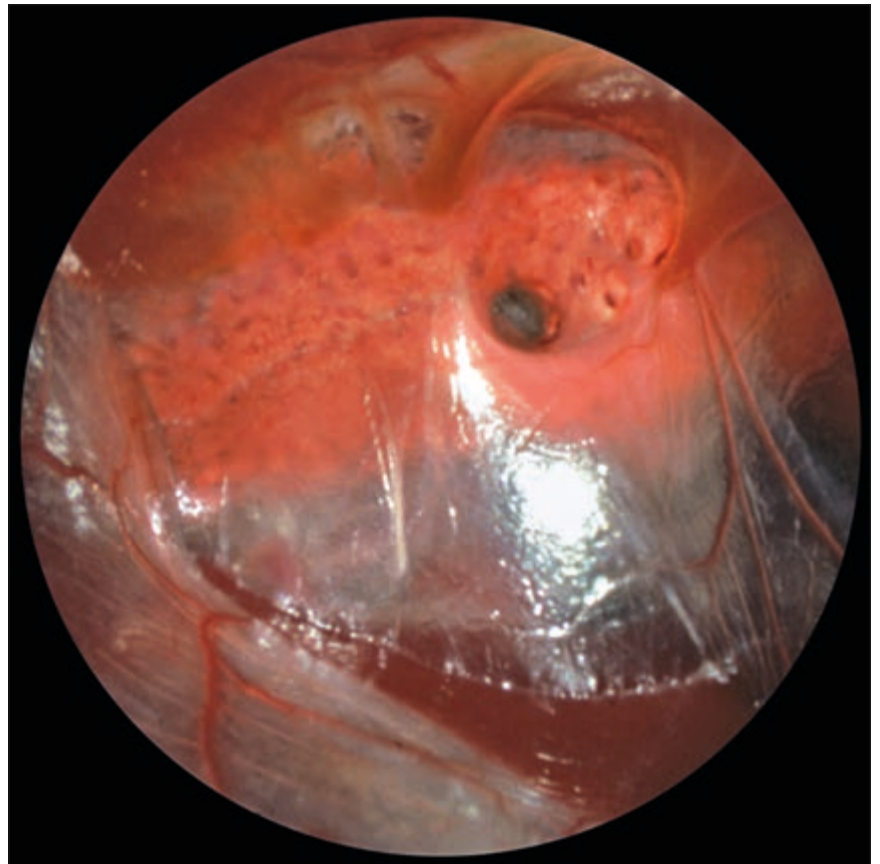


14 Chronic air sac granuloma.
White capped pionus (*Pionus senilis*).
Common avian response to large accumulations of debris.



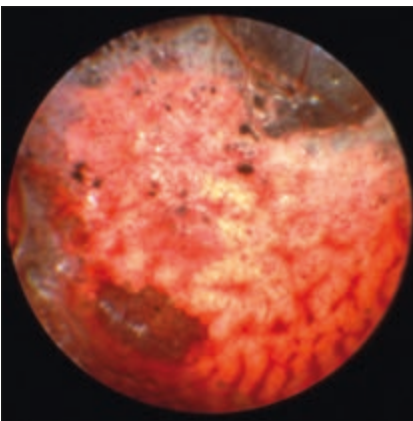
15 Large air sac rent.
Orange winged amazon (*Amazona amazonica*).
This unnecessarily large hole in the air sac was created using an otoscope speculum instead of a fine diameter endoscope.

1.6.2 Lungs

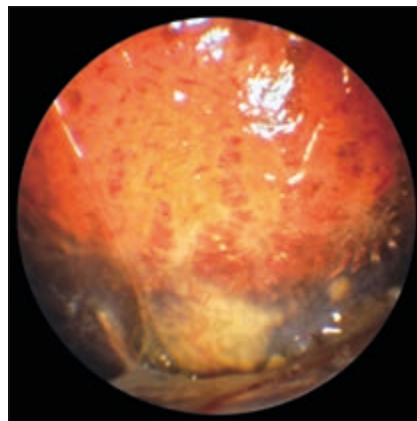


16 Normal lung.
Orange winged amazon (*Amazona amazonica*).

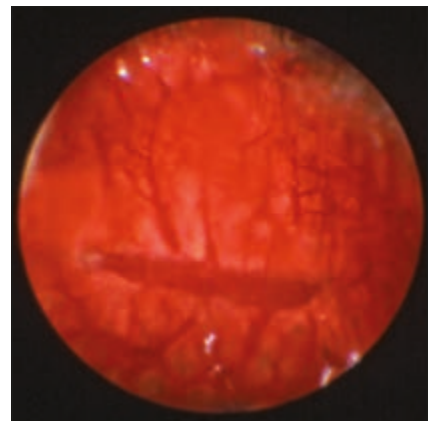
▼ Pathological Alterations



17 Pneumoconiosis.
Blue fronted amazon (*Amazona aestiva*).
The multifocal, black areas in the lung represent accumulations of inhaled carbon particulates.



18 Granulomatous pleuritis.
Yellow shouldered amazon (*Amazona barbidensis*).
This granulomatous debris has accumulated in the pleural space between the air sac wall and the lung.

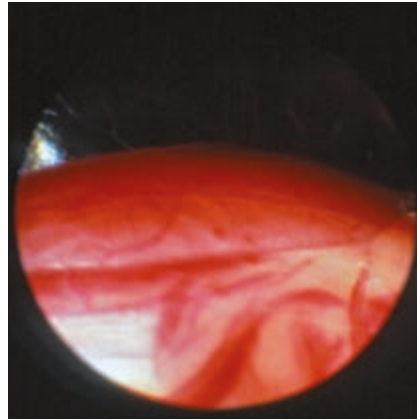


19 Pulmonary congestion and chronic inflammation.
Blue and yellow macaw (*Ara ararauna*).
This pattern of lung inflammation is commonly seen in chronic obstructive pulmonary disease of macaws.

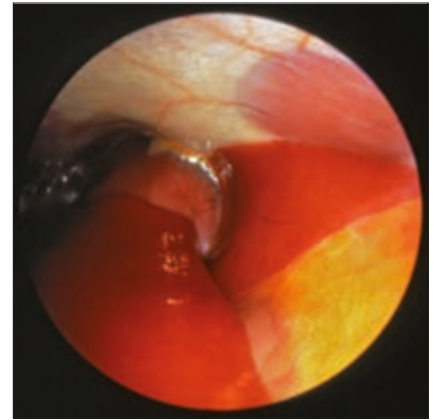1.6.3 Liver

▼ Pathological Alterations

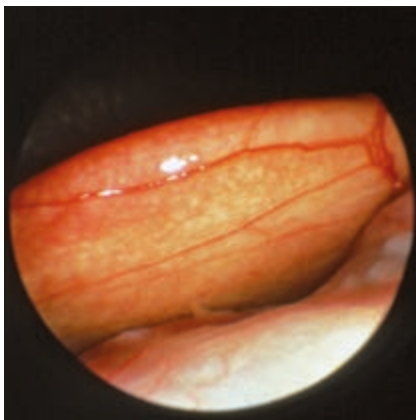
Figs. 22–25



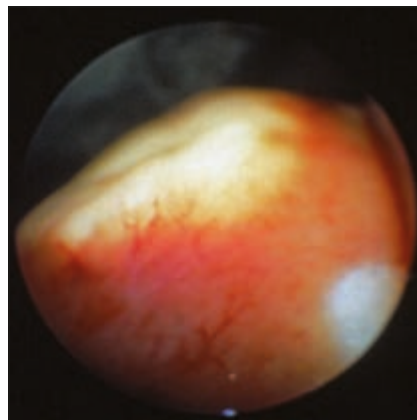
20 Normal hepatic border.
Green winged macaw (*Ara chloroptera*).
View from the left caudal thoracic air sac.




21 Normal liver.
Pigeon (*Columbia livia*). Left and right lobes of the liver viewed from the midline approach to the ventral hepatic peritoneal cavities. Note the lack of a ventral mesentery separating the left and right cavities in this pigeon.



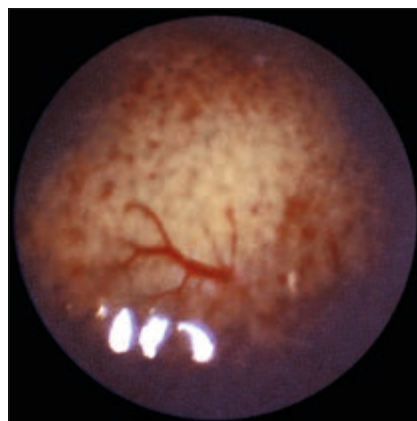
22 Amyloidosis of the liver.
Trumpeter swan (*Olor buccinator*).
The left lobe of the liver is pale brown to tan and swollen.



23 Bile duct carcinoma.
Yellow headed amazon (*Amazona ochracephala*).
Proliferating bile ducts appear as white, raised nodules.

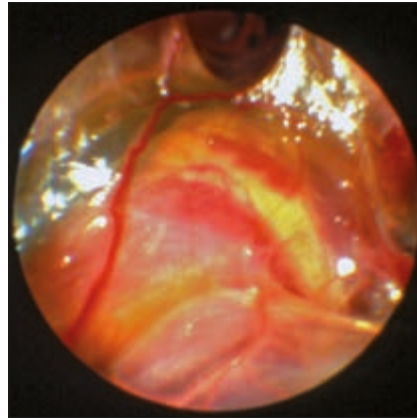


24 Biopsy of the liver.
Orange winged amazon (*Amazona amazonica*).
Left lobe of the liver approached from the caudal thoracic air sac via an incision into the ventral hepatic peritoneal cavity.

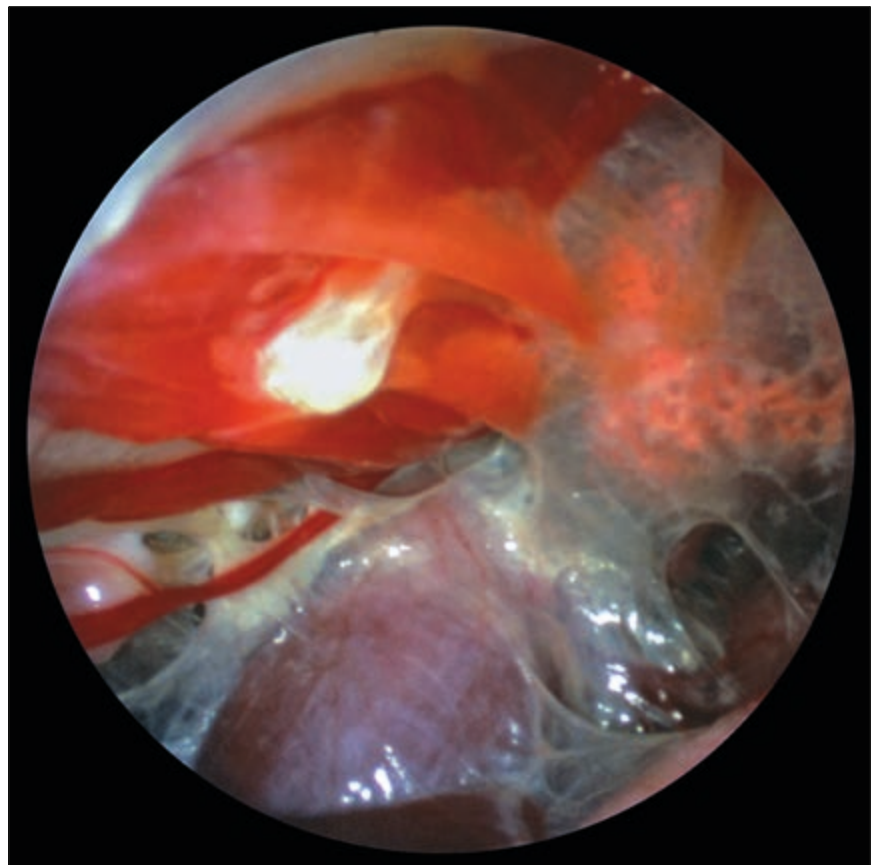


25 Chlamydiosis.
Red-lored amazon (*Amazona autumnalis*).
Marked biliverdin staining of the hepatic parenchyma.

1.6.4 Heart and Pericardial Sac

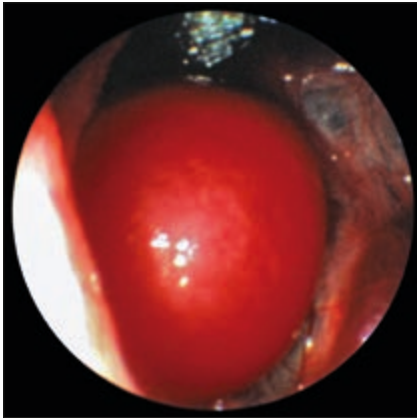


26 Pericardial effusion.
King Parrot (*Alisterus amboinensis*).
Pericardial effusions are relatively common
in systemic diseases of birds.
This parrot had avian chlamydiosis.

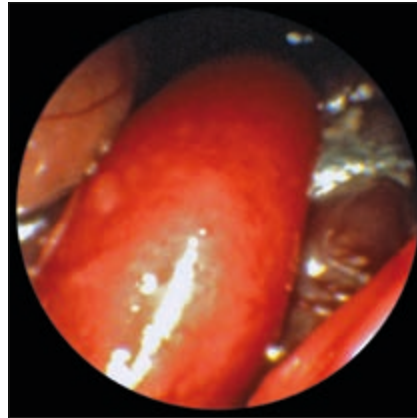


27 Normal heart.
Blue fronted amazon (*Amazona aestiva*).

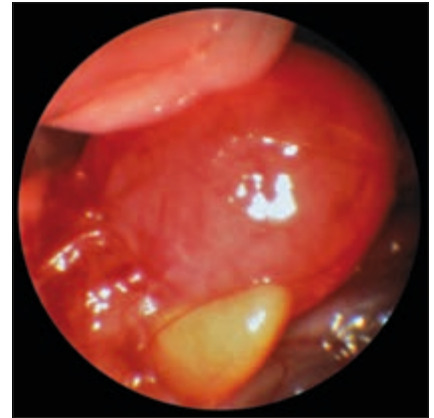
1.6.5 Spleen



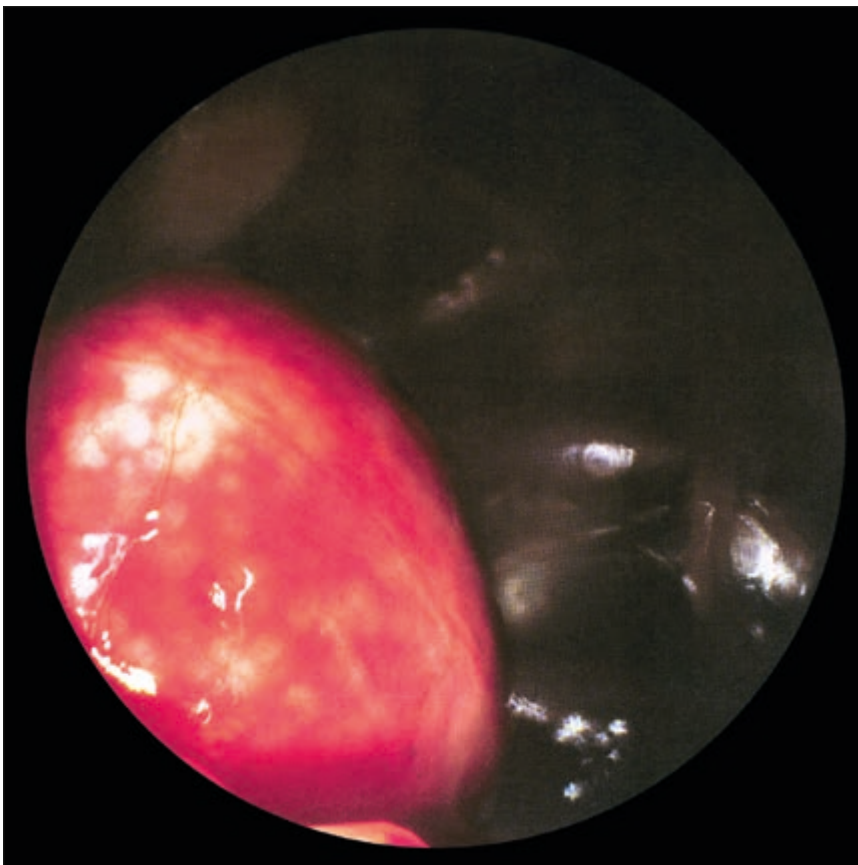
28 Normal spleen.
Blue and yellow macaw (*Ara ararauna*).
Typical rounded spleen of psittacines.



29 Normal spleen.
Indian hill mynah (*Gracula religiosa*).
Sausage shaped spleen of passerines.



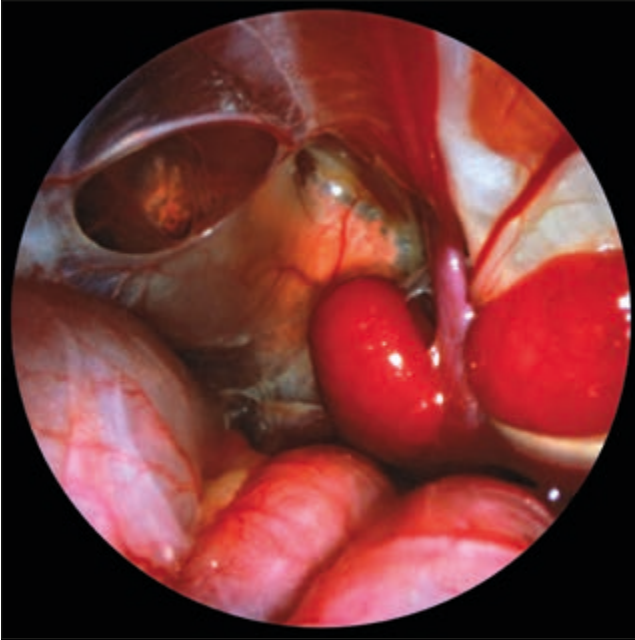
30 Normal spleen and splenic lobe of pancreas.
Orange winged amazon (*Amazona amazonica*).
The splenic lobe of the pancreas is frequently visible near the gastric border of the spleen.



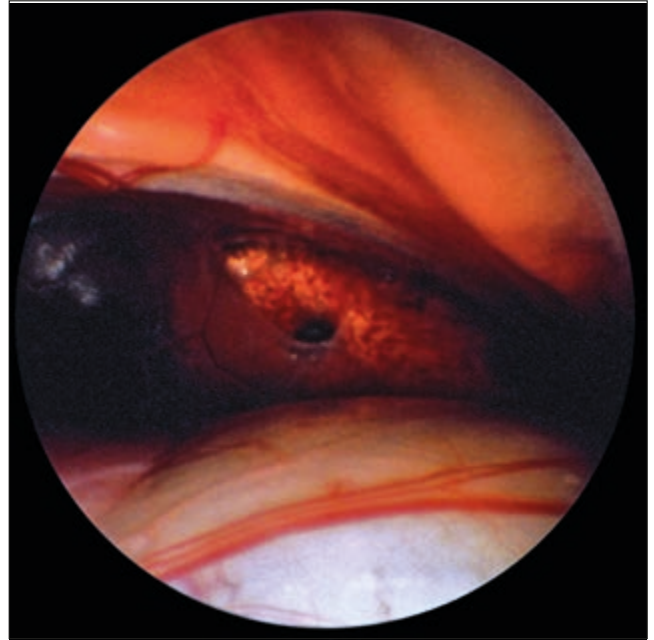
31 Splenic enlargement.
Umbrella cockatoo (*Cacatua alba*).
Enlargement of the spleen can occur in a variety of systemic diseases of birds.

◀ Pathological Alterations

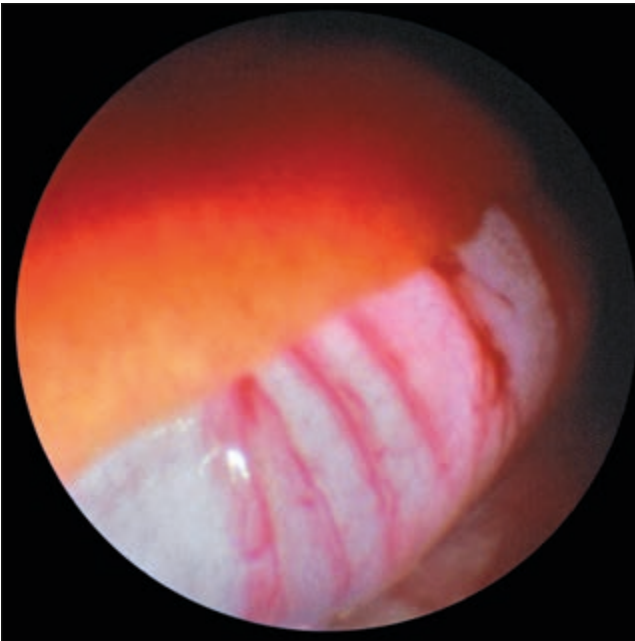
1.6.6 Gastrointestinal Tract



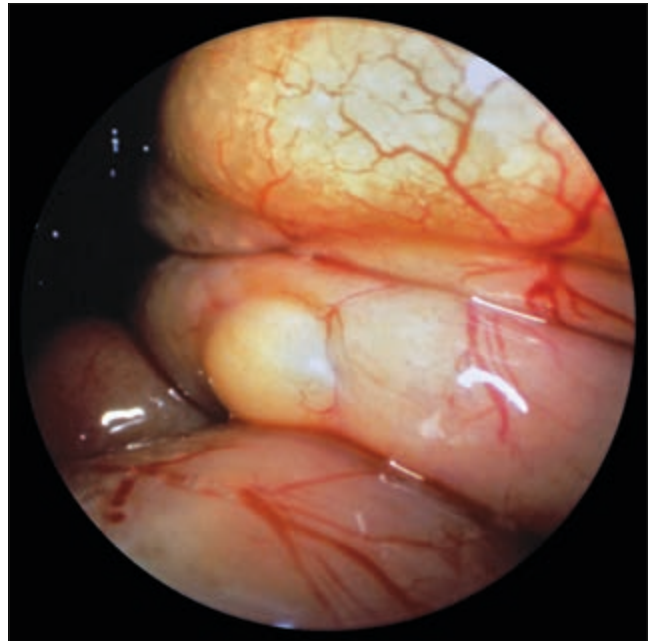
32 Normal intestinal loops.
Orange winged amazon (*Amazona amazonica*).



33 Proventricular dilation.
Orange winged amazon (*Amazona amazonica*).
A large portion of the proventriculus can be viewed from the caudal thoracic and abdominal air sacs. In this case the proventriculus is more dilated than normally expected for this species. In birds that consume large meals (eg. raptors) this appearance may be normal.

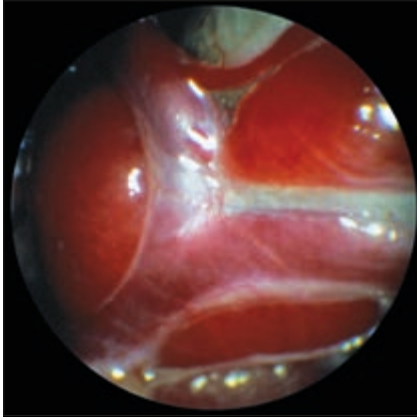

34 Normal duodenum and pancreas.
Green winged macaw (*Ara chloroptera*).

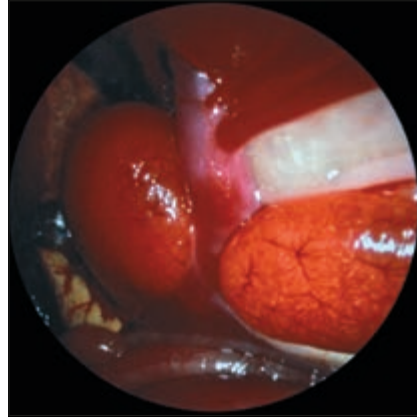


35 Serosal granulomas of avian mycobacteriosis.
Blue headed pionus (*Pionus menstruus*).
Raised subserosal granulomas are frequently found on the intestinal loops of parrots suffering from avian mycobacteriosis.

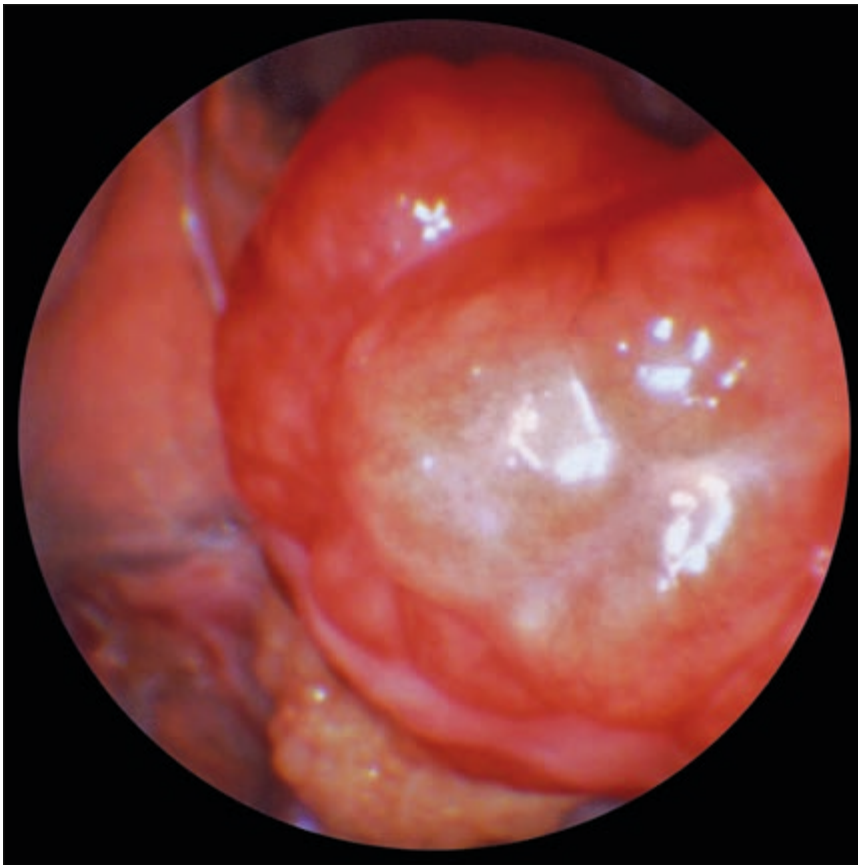
1.6.7 Kidney



36 Normal kidney.
Umbrella cockatoo (*Cacatua alba*).
Normal cranial and middle divisions of the kidney. The ureter is visible as it emerges from behind the iliac artery and vein.

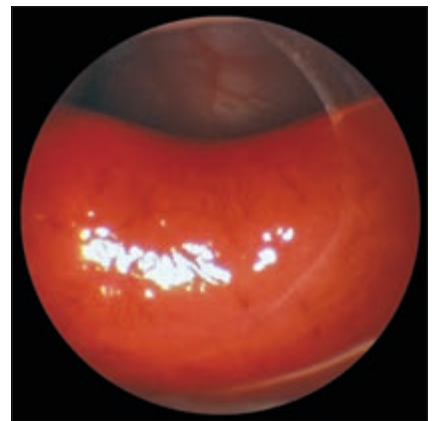


37 Urates in tubules.
Orange winged amazon (*Amazona amazonica*).
Urates may become visible in kidney tubules during normal as well as abnormal renal physiology. This bird was clinically dehydrated but otherwise normal.



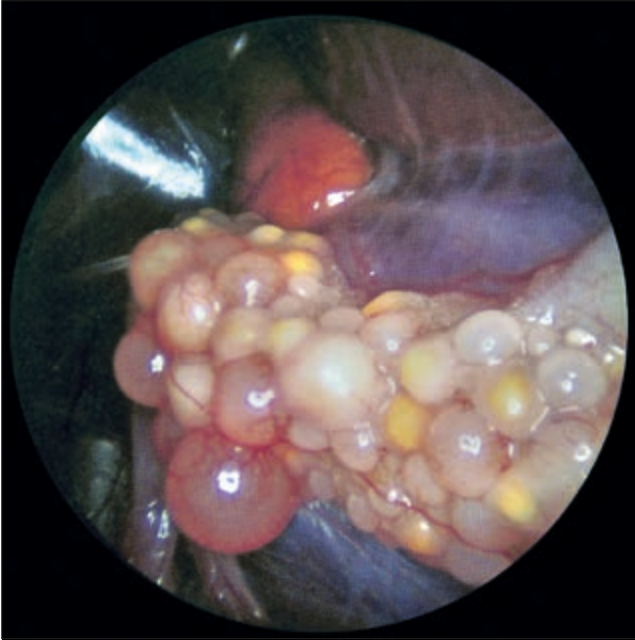
38 Chronic renal disease.
Green cheeked amazon (*Amazona viridigenaia*).
This bird has suffered chronic renal changes due to ongoing kidney disease.

◀ Pathological Alterations

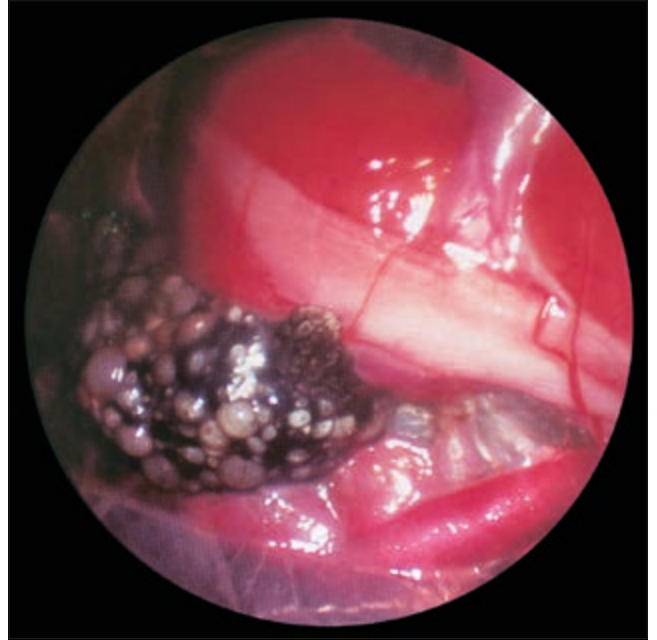

39 Fusion of the middle and caudal divisions.
Orange winged amazon (*Amazona amazonica*).
Fusion may occur for developmental reasons or occasionally due to pathology.

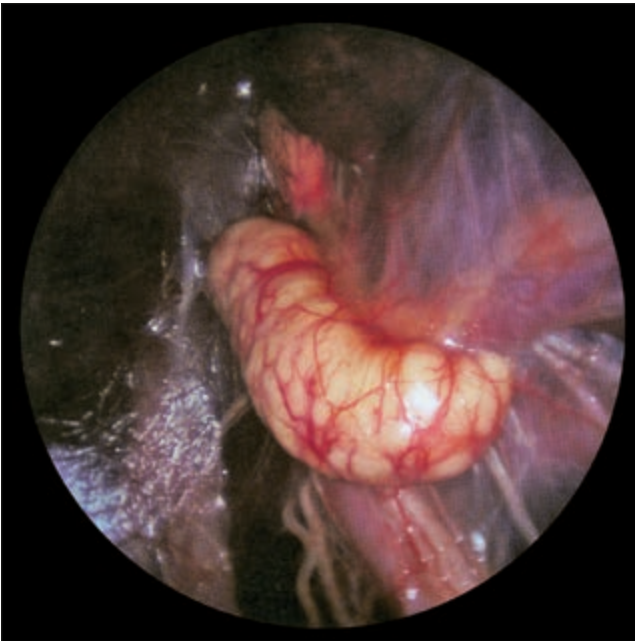
1.6.8 Gonads



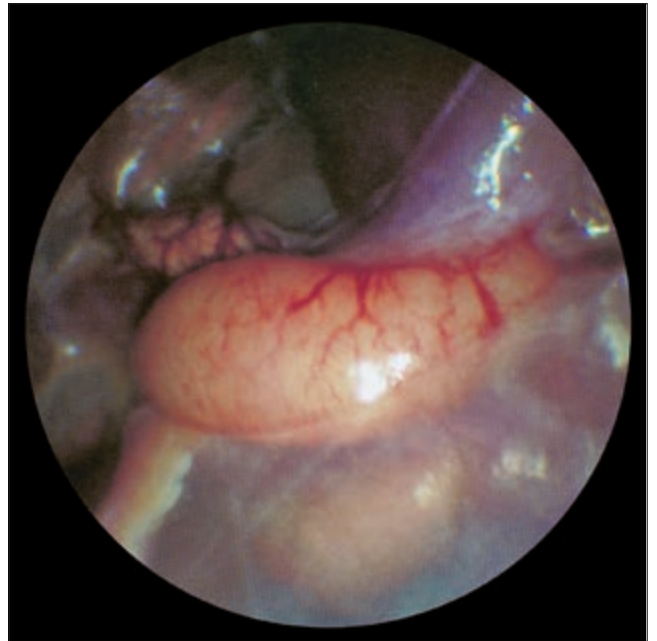
40 Normal mature ovary.
Red-tailed hawk (*Buteo jamaicensis*).
This unpigmented ovary has a typical "cluster of grapes" appearance. In most species only the left testicle develops after hatching.



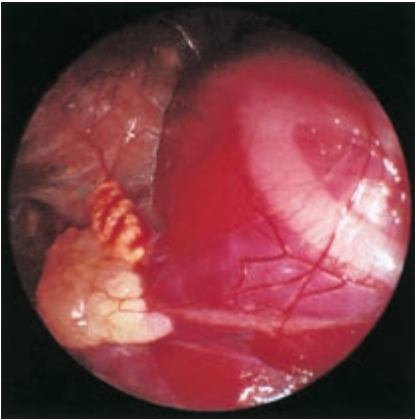
41 Normal mature ovary.
Umbrella cockatoo (*Cacatua alba*).
In some species the ovary and/or the testicle may be melanistic.



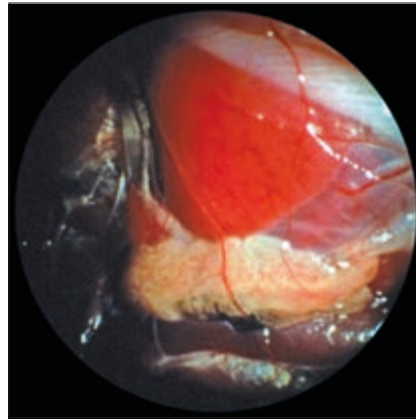
42 Normal mature testicle.
Trumpeter swan (*Olor buccinator*).
The mature testicle has a bean-shaped appearance.



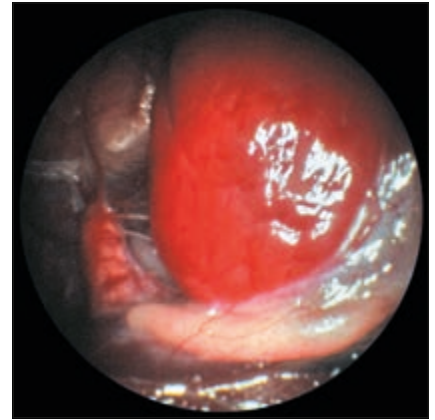
43 Normal mature testicles.
Yellow-headed amazon (*Amazona ochrocephala*).
Frequently the right testicle may be viewed through the dorsal mesentery.

**44 Normal immature ovary.**

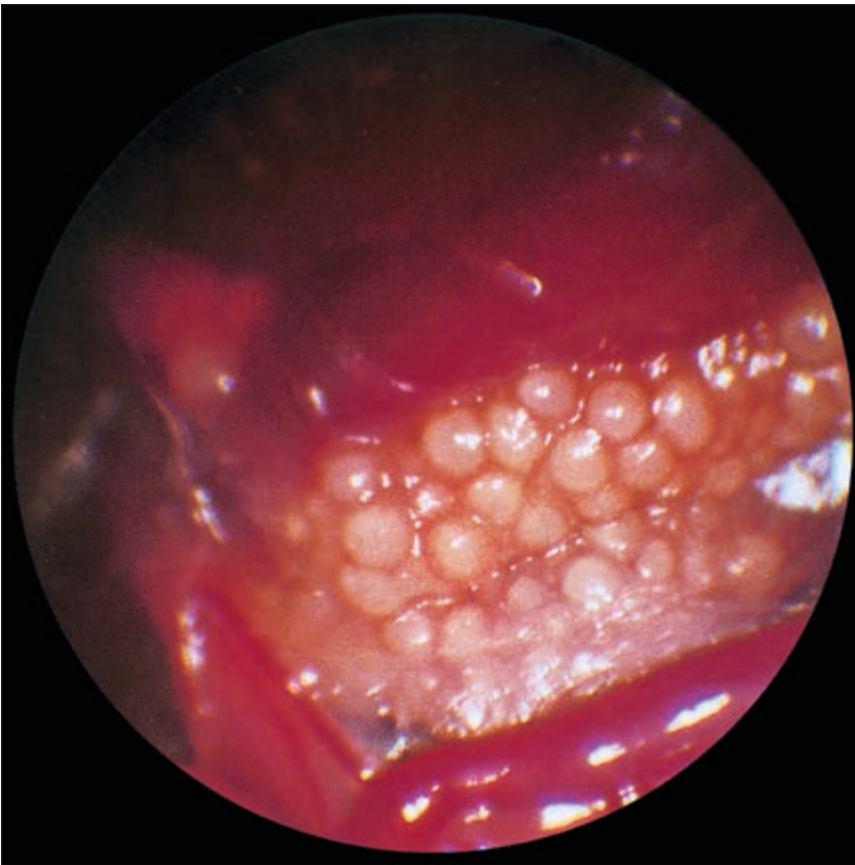
Tucuman amazon (*Amazona tucumana*). The immature ovary has sulci and gyri reminiscent of the surface of the brain. Primary follicles are not yet clearly evident. The prominent dorsal ligament of the ovary is visible crossing the cranial division of the kidney.

**45 Normal immature ovary.**

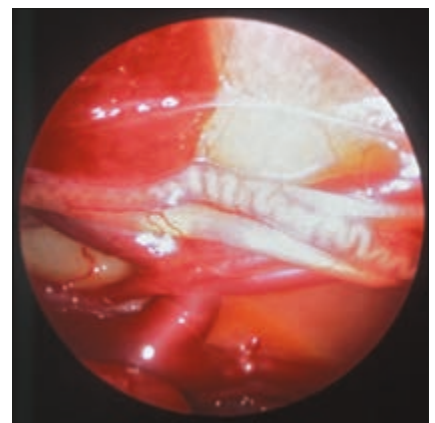
Blue and yellow macaw (*Ara ararauna*). In some species the ovary may be partially or fully melanistic. This macaw exhibits partial melanism.

**46 Normal immature testicle.**

Green winged macaw (*Ara chloroptera*). The immature testicle is quite different from the immature ovary. It is three-dimensionally raised and sausage shaped.

**48 Normal mature ovaries.**

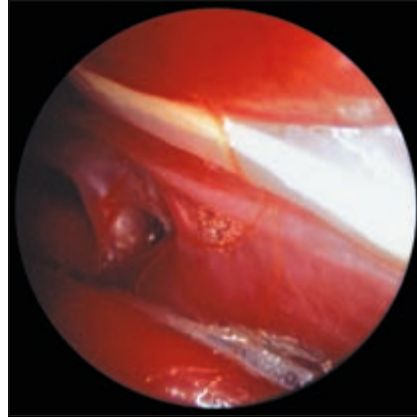
Sharp-shinned hawk (*Accipiter striatus*). Some species such as the Accipiters develop a prominent right ovary. Here the right ovary is seen near the left giving a "horseshoe" appearance.

**47 Mature ductus deferens.**

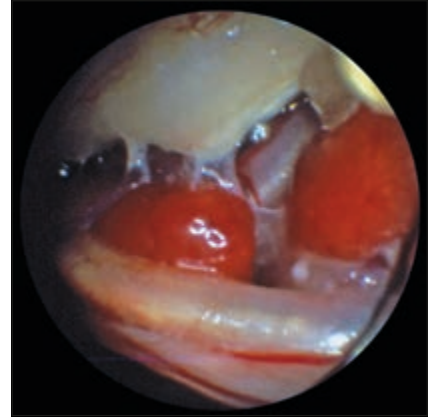Yellow headed Amazon (*Amazona ochrocephala*). The ductus deferens of the hormonally active male bird becomes very sinuous.

1.6.9 Ureters

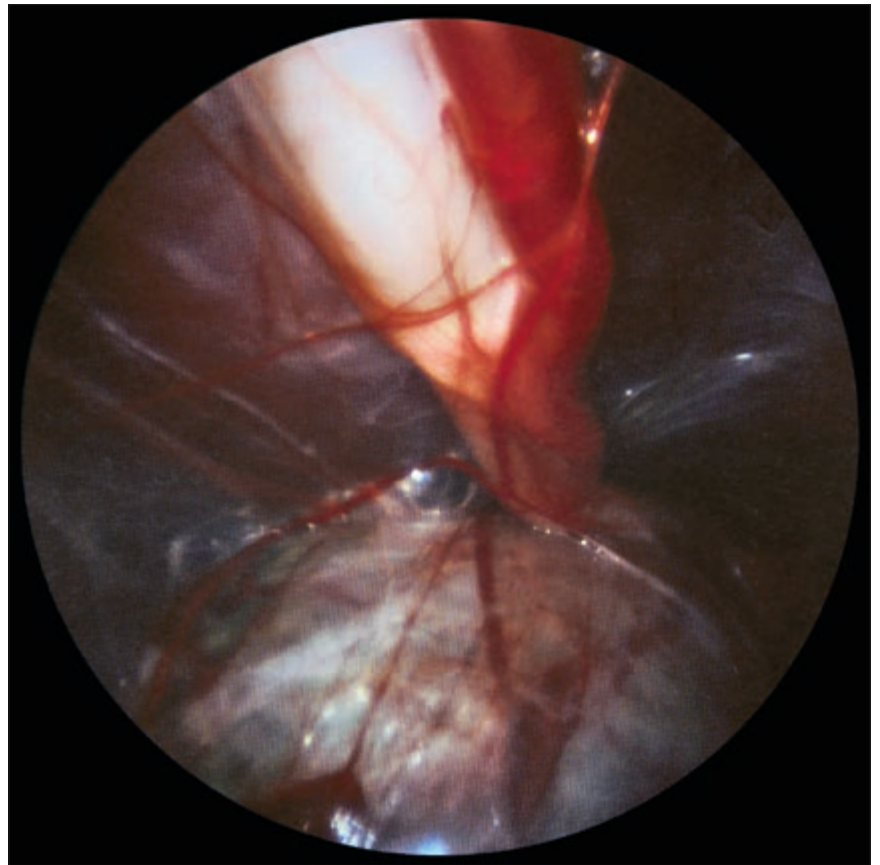
▼ Pathological Alteration



49 Normal ureter.
Blue and yellow macaw (*Ara ararauna*).



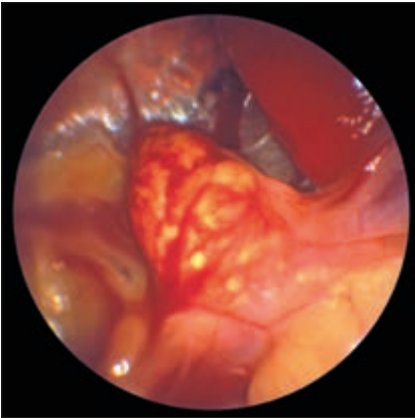50 Ureteral dilation.
Green cheeked amazon
(*Amazona viridigenalis*).



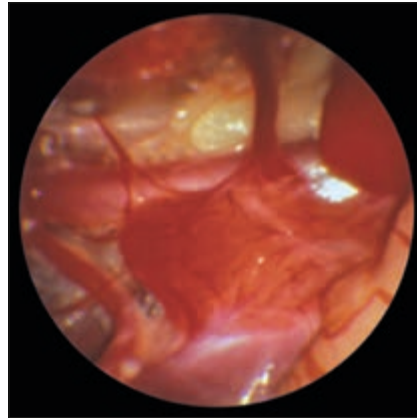
51 Normal ureter entering the urodeum.
Trumpeter swan (*Olor buccinator*).

1.6.10 Adrenal Glands

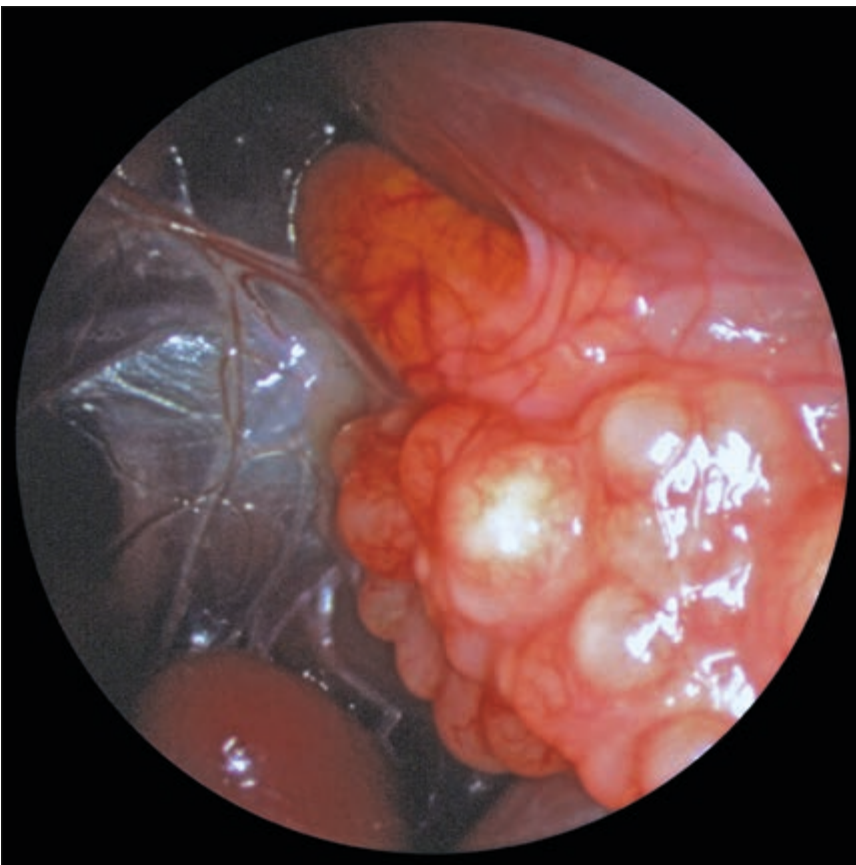
▼ Pathological Alterations



52 Adrenal Gland.
Blue Fronted Amazon
(*Amazona aestiva*).



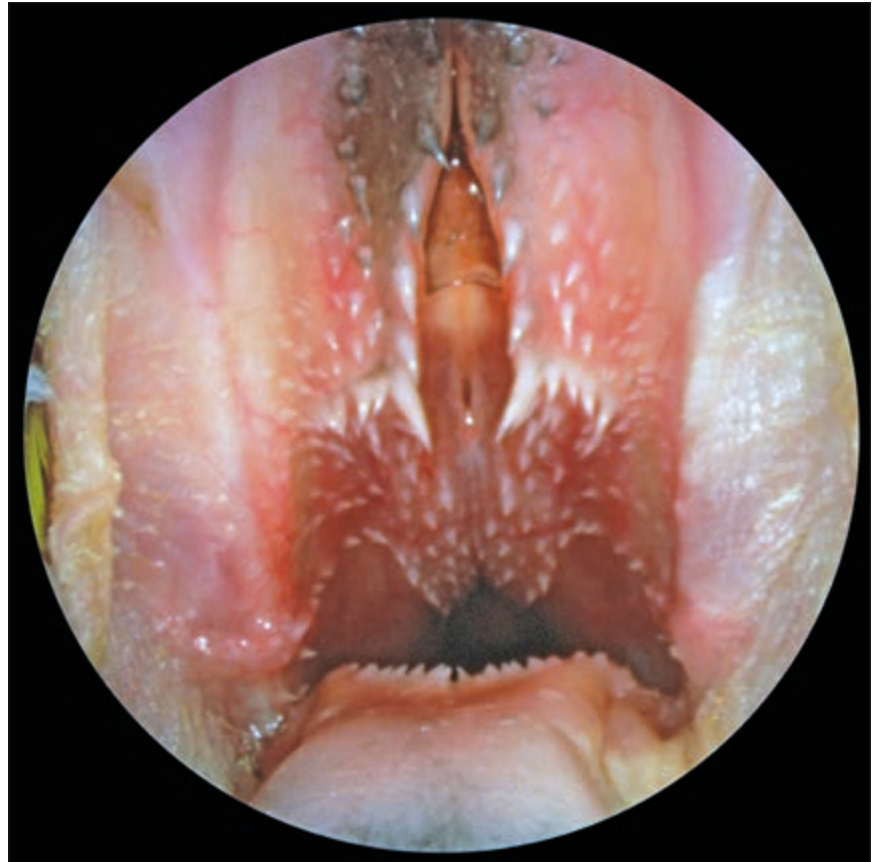53 Adrenal congestion.
Blue and gold macaw (*Ara ararauna*).
This adrenal gland is abnormally congested with a dark, meaty texture.



54 Adrenal gland.
Red tailed hawk (*Buteo jamaicensis*).
Note the normal yellow colour of the adrenal gland of this carnivorous bird.

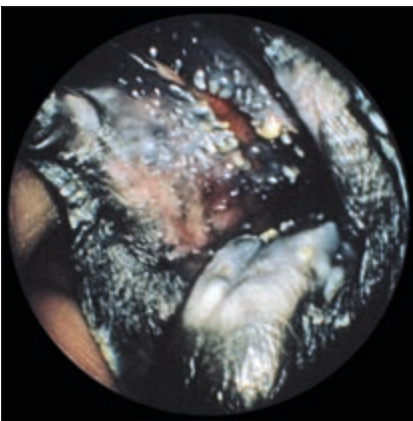
1.7 Non Invasive Endoscopy in Birds

1.7.1 Oral Cavity

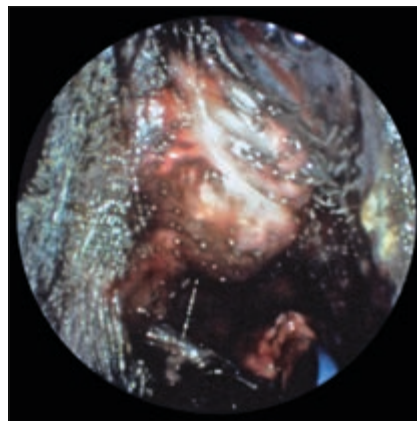


55 Normal oropharynx.
Yellow crowned amazon (*Amazona ochrocephala*).

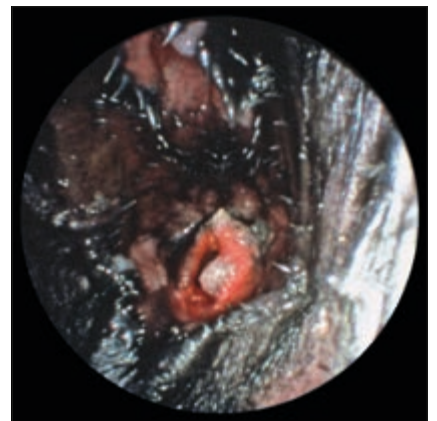
▼ Pathological Alterations



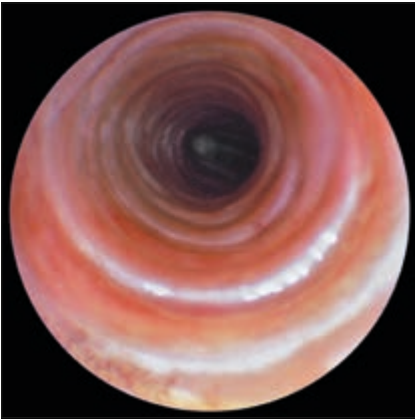
56 Chronic hypovitaminosis A.
Yellow naped amazon (*Amazona ochrocephala*).
Note the white, inspissated appearance of the salivary lingual glands.



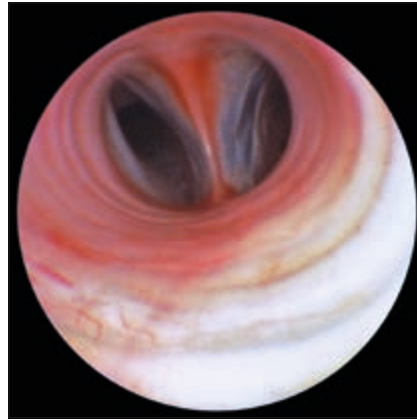57 Palatine abscess.
Yellow naped amazon (*Amazona ochrocephala*).
Unlike the inspissated appearance that occurs with hypovitaminosis A, this abscess contained a pure culture of bacteria.



58 Glottal papillomatosis.
Yellow naped amazon (*Amazona ochrocephala*).
A virus is implicated as the cause of these oropharyngeal (and cloacal) papillomas. They may be difficult to detect without the illumination and magnification that the endoscope affords.

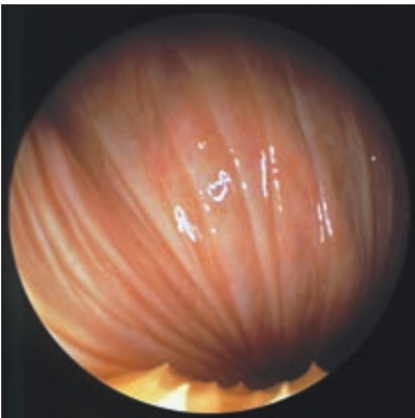


59 Normal trachea.
Orange winged amazon (*Amazona amazonica*).
Note the syringeal folds visible at the base.

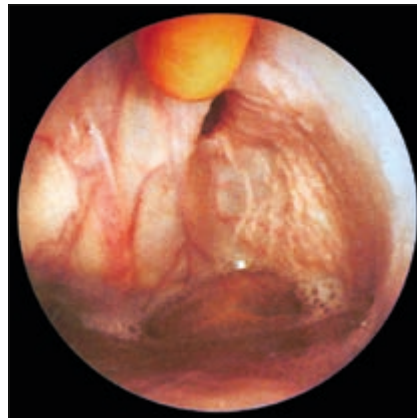


60 Normal trachea.
Red tailed hawk (*Buteo jamaicensis*).
Unlike the parrot the hawk has a simple syrinx with little syringeal development.

1.7.2 Trachea

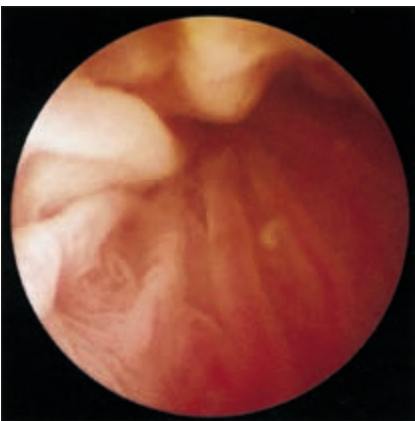

61 Oropharynx and esophageal folds.
Great Horned Owl (*Bubo virginianus*).
Birds that consume large boluses of food have noticeable folds of the esophageal mucosa.

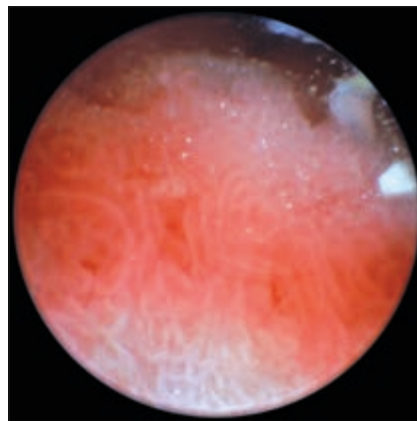


62 Ingluvies and esophageal sphincter of the thoracic esophagus.
Moluccan Cockatoo (*Cacatua moluccensis*).
The esophageal sphincter is open due to the degree of insufflation present.

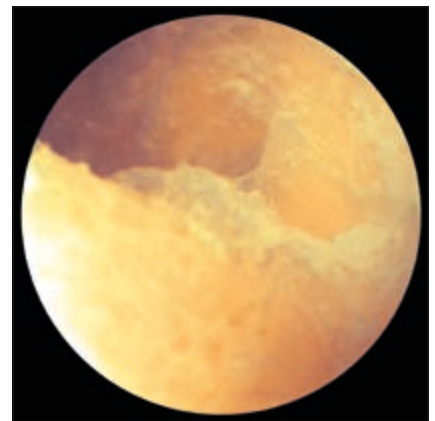
1.7.3 Esophagus, Ingluvies, Proventriculus and Ventriculus



63 Esophageal sphincter of the thoracic esophagus.
Green winged macaw (*Ara chloroptera*).
A magnified view of the foliate appearance of the closed sphincter that empties the ingluvies into the thoracic esophagus.



64 Proventricular mucosa.
Pigeon (*Columba livia*).
The proventricular glands can be seen as distinct round openings.

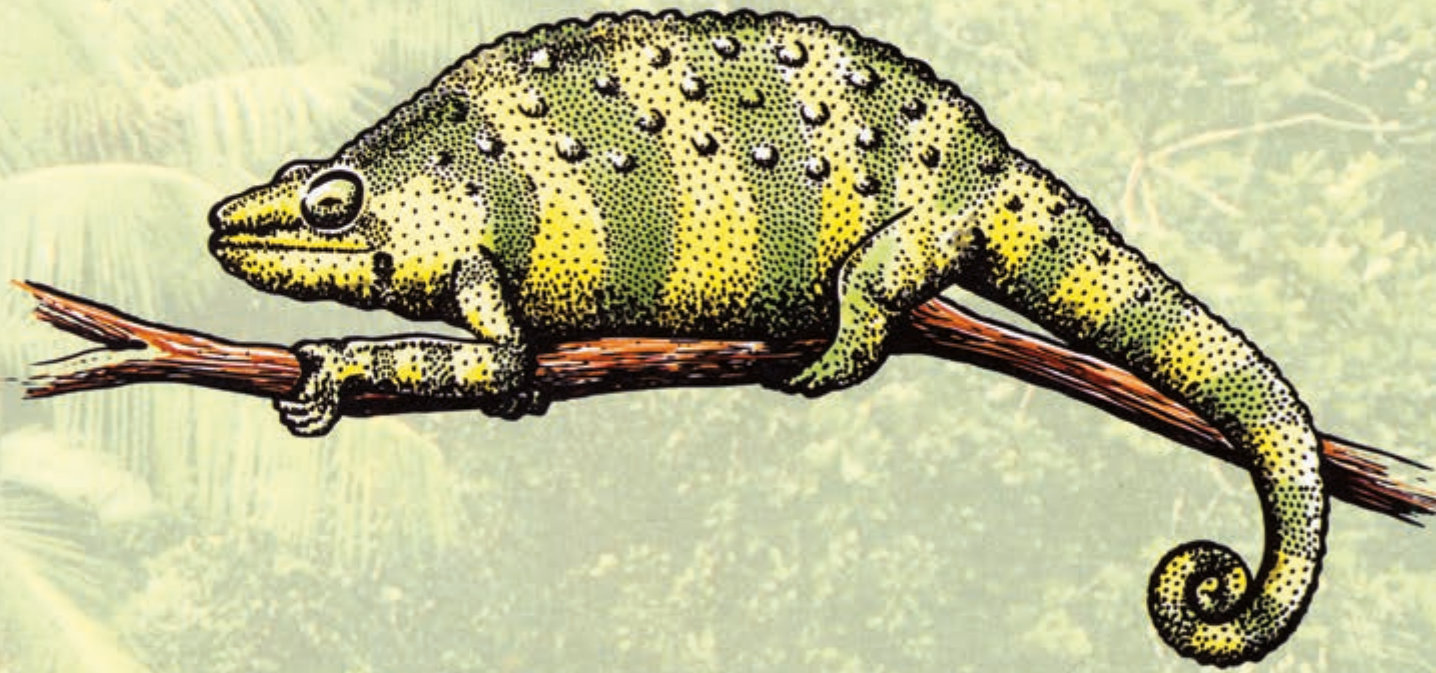

65 Ventriculus.
Green winged macaw (*Ara chloroptera*).
Note the bile staining of the koilin layer.

1.8 Literature

1. HARRISON GJ: Endoscopic examination of avian gonadal tissue
Vet Med Small Anim Clin 73:479-484, 1978.
2. JONES DM et al: Sex determination of monomorphic birds by
fibreoptic endoscopy. Vet Rec 115:596-598, 1984.
3. KOLLIAS GV: Liver biopsy techniques in avian clinical practice.
Vet Clin North Am 14(2):287-298, 1984
4. LUMEIJ TJ: Endoscopy. In A Contribution to Clinical Investigative
Methods for Birds with Special Reference to the Racing Pigeon
(Columbia livia domestica). Utrecht, 1987, pp 151-166.
5. McDONALD SE: Surgical sexing of birds by laparoscopy.
Calif Vet 5:16-22, 1982.
6. SATTERFIELD W: (1981). Early diagnosis of avian tuberculosis by
laparoscopy and liver biopsy. In Recent Advances in the Study of
Raptor Diseases, (eds) J.E.Cooper and A.G. Greenwood,
Chiron Publications, Keighley, UK pp 105-106.
7. TAYLOR M: Diagnostic application of a new endoscopic system for
birds. Proc Eur Conf Avian Med Surg, Utrecht, NL, 1993, pp 127-131.
8. TAYLOR M: Endoscopic examination and biopsy techniques.
In: Ritchie BW, Harrison GJ, Harrison LR (eds). Avian medicine:
principles and application. Lake Worth, FL: Wingers Publishing Inc,
1994:327-354.

ENDOSCOPY IN REPTILES AND AMPHIBIANS



**Bernd SCHILDGER, DVM,
Zoological Garden Dählhölzli,
Bern, Switzerland**

Endoscopy in Reptiles and Amphibians

Bernd SCHILDGER, DVM

Director

Tierpark Dählhölzli

Tierparkweg 1

CH-3005 Bern, Switzerland

Phone: +41-3 1357 15 15

Fax: +41-3 1357 15 10

2.0 Endoscopy in Reptiles and Amphibians

2.1 Introduction

Endoscopy in reptiles and amphibians has developed from a method to identify the sex of monomorphic reptiles to an important diagnostic tool in reptile medicine.

The techniques are readily learned. The interpretation of the results doesn't require years of experience like in ultrasonography. During endoscopic exploration the inner organs appear in their natural size, shape, position and colour. Surface alterations can easily be diagnosed. Even very small structures (less than 1 mm in size) like juvenile ovaries or mycobacterial granulomas in small reptiles (less than 20 g BM) are visible. Modern endoscopic equipment permits the sterile biopsy of organs for further microbiological or histological examination and the removal of foreign bodies or parasites. In addition endoscopic equipment is less expensive than other diagnostic imaging methods. Using one basic equipment set, for example the 2.7 mm 30° rigid endoscope, the surgeon is able to examine reptiles from 50 g to 20 kg.

Endoscopy is of great value in reptile medicine because many of the commonly used mammalian clinical techniques such as measurement of body temperature, respiration and heart rates and palpation of lymph nodes are of only limited value.

Endoscopic examination of the pleuro-peritoneal cavity (coelioscopy) in reptiles was first described for *Chelodina mydas* by WOOD et al. (1983). Predicting the sex and stage of gonadal development has been described for various lizard and chelonian species such as *Trachydosaurus rugosus*, *Tiliqua spp.*, *Heloderma spp.*, *Varanus spp.* and *Chelodina spp.* (KUCHLING 1989, HAEFELI 1994, SCHILDGER and WICKER 1987, 1992, SCHILDGER et al. 1993, 1998). Coelioscopy soon developed into a method of clinical diagnostic imaging of inner organs like the heart, liver, lungs, intestines and kidneys (SCHILDGER and WICKER 1992, SCHILDGER et al. 1994, SCHILDGER 1995).

Non invasive endoscopic examination in reptiles has rarely been published. In 1982, COPPOOLSE first described the examination of the cloaca in reptiles. COOPER and SCHILDGER (1991) portrayed oesophagoscopy in chelonians. Gastroscopic techniques in chelonians were specified by SCHILDGER (1997). Endoscopic examination of the respiratory tract in reptiles (tracheoscopy and pulmonoscopy) were described by GOEBEL and JURINA (1994).

Amphibians display a pleuroperitoneal cavity as undivided as most of the lizards. Coelioscopy was used to identify the sex (*e.g. Andrias davidianus*) and for diagnostic imaging of inner organs (SCHILDGER and WICKER 1992).

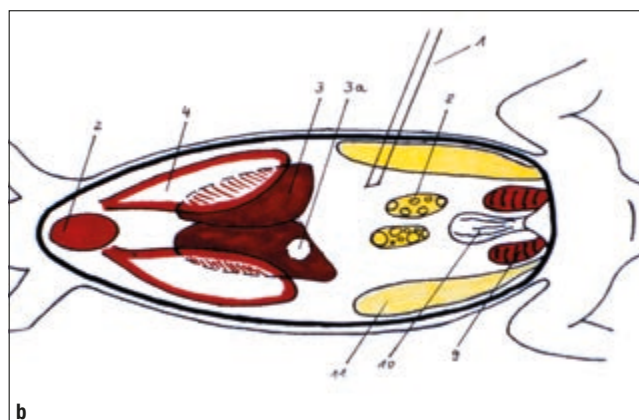
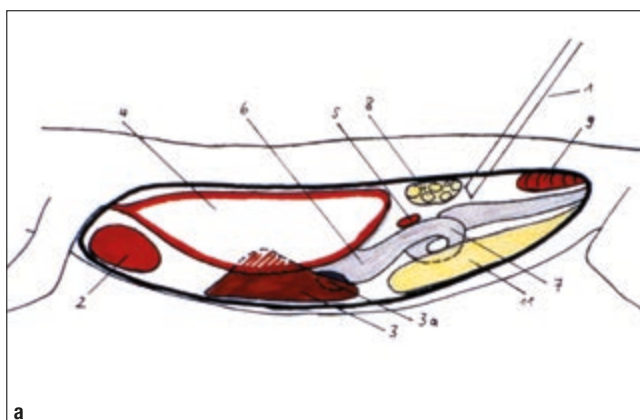
The methods for endoscopic examination of reptiles and amphibians have been established. The following chapters should allow the reader to evolve impressions about the endoscopic appearance of normal and pathologically altered organs and to use this powerful tool in reptile medicine.

2.2 Anatomy

Primitive reptiles, such as most of the lizards, possess an undivided paraperitoneal cavity. The only separate compartment is the pericardium. It is placed far cranially in the pleuroperitoneal cavity, between the shoulder joints. Genera of the families *Scincidae*, *Iguanidae*, *Helodermatidae*, *Agamidae* and *Geckonidae* belong to this group. In monitors and crocodiles a *septum postpulmonale* separates the peritoneal cavity from the pleural cavity which is divided into two bilaterally symmetric cavities by the mediastinum (DUNKER 1978). The *descensus cordis* in monitors leads to the heart and liver placed caudally, close to the center of the body cavity. The intestines are only fixed dorsally by the mesentery. Ventrally, the left and right peritoneal cavities communicate. In Chelonians, the lungs are fixed dorsally, adherent to the carapace. They are separated ventrally from the other inner organs by a *septum horizontale*. Both the *septum postpulmonale* and the *septum horizontale* are translucent. It is possible to examine the lungs endoscopically through the septum. In lizards, two symmetric fat bodies are placed retroperitoneally and laterally. They originate close to the pelvis and may extend far cranially (lateral to the heart) in obese animals. The more or less uncompartmented pleuroperitoneal cavity in most of the lizards and chelonians permits the endoscopic examination of gonadal structures, kidneys, bladder, liver, spleen, intestines and lungs using a single approach. In snakes, the point of entry for the endoscope must vary with the organ to be examined because of the elongated anatomy.

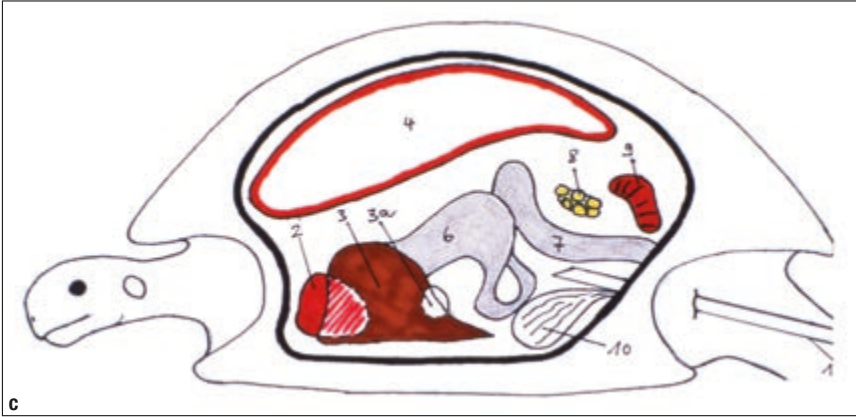
Anatomical principles in Lizards (Iguanids), Chelonians and Snakes, different endoscopic routes to enter the pleuroperitoneal cavity

- | | |
|----------------------------|-----------------|
| 1 = Endoscope, introduced, | 6 = Stomach, |
| 2 = Heart, | 7 = Intestines, |
| 3 = Liver, | 8 = Gonads, |
| 3a = Gallbladder, | 9 = Kidneys, |
| 4 = Lungs | 10 = Bladder |
| 5 = Spleen, | 11 = Fat bodies |

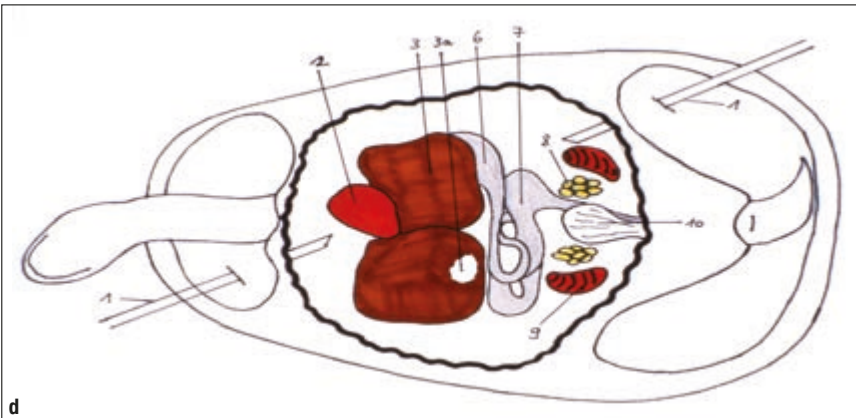


1 Lizard, laterolateral.

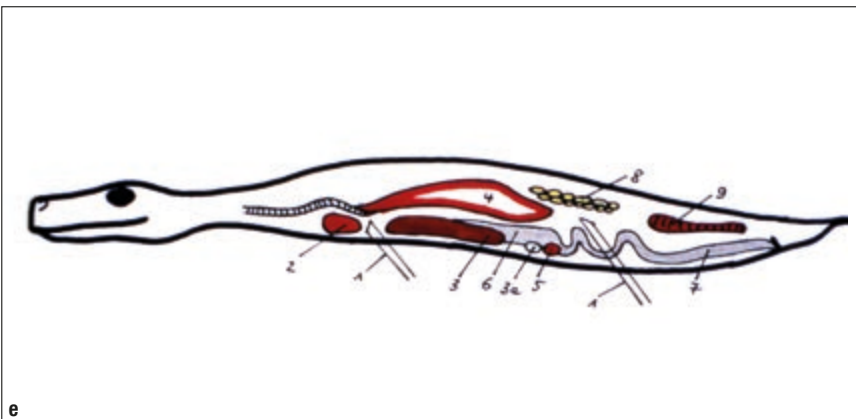
Lizard, dorsoventral.



c Chelonian, laterolateral.



d Chelonian, dorsoventral.



e 1 Snake, laterolateral.

2.3 Indications

Indications for Endoscopy in Reptiles

- **Sex identification of monomorphic reptiles**
(e.g., *Varanidae*, *Scinciciae*, *Helodermatidae*, *Chelidae*)
- **Sex identification in juvenile reptiles**
(monomorphic and dimorphic species)
- **Staging and Control of reproductive state**
(e.g., endangered species breeding programs)
- **Diagnostic imaging of internal organs**
(suspected diseases such as gout, abscesses, tumors, ascites, mycobacteriosis, arteriosclerosis, amoebiasis)
- **Removal of foreign bodies or parasites**
(*Filariae*, *Austramphilina spp.*, *Pentastomides*)
- **Endoscopic surgery**
(sterilization, castration, splenectomy)

2.4 Anesthesia

Endoscopic examination of the pleuroperitoneal cavity in reptiles is invasive and therefore requires anesthesia. In former times this was the greatest disadvantage of endoscopy in reptiles. With modern anesthetics such as isoflurane (Forene®, Abbott), there is little risk to anesthetize reptiles for these procedures. In 700 cases the mortality rate associated with the anesthesia and endoscopic examination of reptiles was zero%. The recommended regime to anesthetize lizards, chelonians and snakes for endoscopic examination is listed below. For species-specific problems it is advisable to refer to the literature (see BENNETT 1991, FRYE 1991, SCHILDGER et al. 1993, GABRISCH and ZWART 1998).

Anesthesia regime for endoscopic examination in lizards, chelonians, snakes

- **Presurgical heating** of the animals to 25 – 35°C (ectothermes)
- **Introduction**
 - Isoflurane 5% in snakes and lizards via face mask
 - Ketamine 50 mg / kg i. p. in tortoises
 - Ketamine 75 mg/kg i. p. in turtles
- **Surgical tolerance**
Intubation, positive pressure insufflation (3–4/min)
Isofluran 4 to 1%
- **Wake up period**
20 – 22 °C, room air ventilation

In most of the chelonians, the ketamine dose is sufficient for short endoscopic examinations (10–15 minutes). The ketamine dosage can vary in some genera. In the crocodylia species, specific dosages and application routes are recommended.



2 Isoflurane anesthesia.
Introduction via face mask, Green Iguana (*Iguana iguana*).

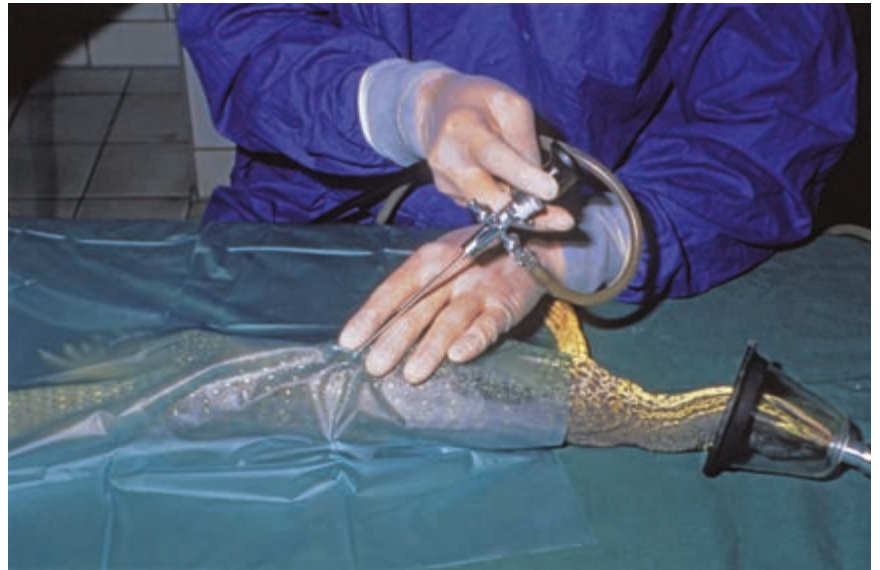


3 Isoflurane anesthesia.
Intubation, positive pressure insufflation. Boid snake (*Corallus caninus*).

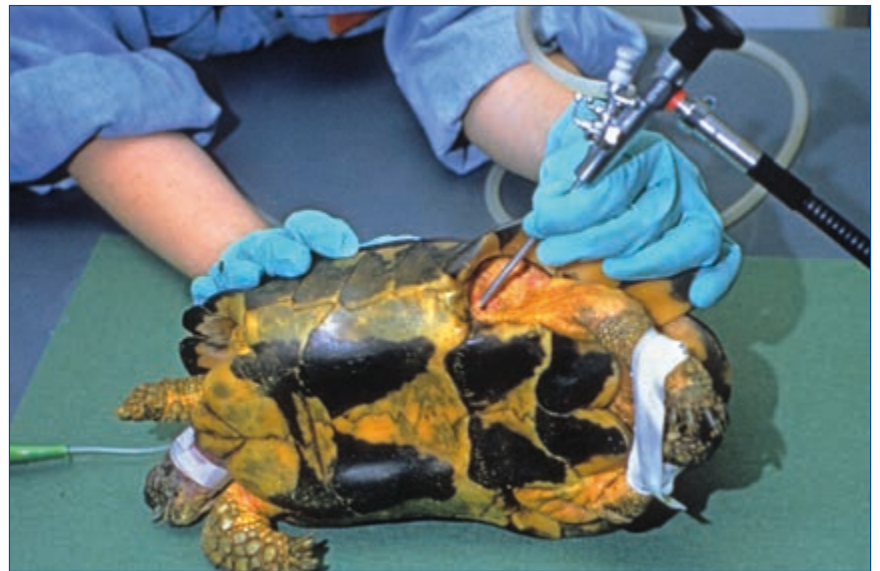2.5 Endoscopic Techniques

2.5.1 Endoscopic Examination of the Pleuroperitoneal Cavity

Pre-endoscopic fasting facilitates endoscopic viewing. The less filled the stomach and intestines are, the greater the space between the front lens and organ to be examined. Carnivorous reptiles like monitors and most of the turtles, with short intestines and short passage time of the ingesta should be fasted between 3 to 7 days. In herbivorous reptiles like *Tiliqua* spp. or *Testudo* spp. fastening time may be extended up to 4 weeks. Under field conditions (free ranging animals) even some hours are sufficient.



4 Endoscopic examination in lizards.
The endoscope is introduced.



5 Endoscopic examination in chelonians.
The endoscope has not been introduced and the tip indicates the point of introduction.

The anesthetized reptile is placed in lateral right recumbancy and fixed (manually or taped). The area for introduction of the endoscope is cleaned, disinfected and covered using a clear, sterile drape. Skin should be incised using scissors. Muscles and peritoneal serosa can be perforated bluntly using either scissors, forceps or a trocar. In cases where the endoscope is used without a sheath (including working channel or verres cannula insufflation) it should be introduced between the smoothed sides of the forceps. In chelonians the scope is introduced in the center of the left knee fold. In lizards the endoscope is inserted at the beginning of the last body third (Figs. 1, 4, 5). In snakes the introduction area depends on the organs which are to be examined. The point of entry can vary in lizards and chelonians too, depending on the target organ. The endoscopic technique for examination of the pleuroperitoneal cavity in amphibians is similar to the one used in lizards.

Insufflation, in addition to fasting, further improves the optical conditions. Especially in small reptiles (< 100 g BM) a good overview of the topographic anatomy can only be achieved with insufflation. The distended body cavity under insufflation enables the examiner to move organs. For example a fat body lying over the gonadal structure can easily be moved ventrally with the tip of the endoscope or biopsy forceps to improve visualization. For endoscopic surgery insufflation is obligatory to extend the working area. Filtered air or medical CO₂ can be used. An insufflation pressure of 10 mmHg is sufficient. The easiest way to realize both is to use an automatic insufflator. Under field conditions a hand held air balloon can be useful. For insufflation of the body cavity a sheath including valves or an endoscope including a working channel and valves should be used. Especially in small reptiles the use of a Verres cannula requiring a second puncture is not useful.

The endoscopes to be used for endoscopic exploration of the pleuroperitoneal cavity should be rigid. The HOPKINS® rod lens system provides a much higher optical quality than any flexible scope can achieve. The diameter is always a compromise between the demand of the examiner for maximum optical view (large diameter) and the right of the patient to the smallest diameter. The diameter used will depend on the size of the reptile to be examined. The 2.7 mm scope with sheath including working channel is a good compromise to examine reptiles of 50 g BM up to 20 kg BM. For smaller reptiles a 1.9 mm scope with sheath or the 3 mm triangular scope including a working channel are recommended. In reptiles, bigger than 500 g BM, a 4-mm-endoscope with sheath provides a superb optical quality even for documentation. Endoscopes with an angled front lens (20°–30°) are preferable. They provide more flexibility to vary the view to an organ.

Rigid endoscopes for examination of the pleuroperitoneal cavity in reptiles (all serial numbers KARL STORZ):

- Diameter 1.9 mm, 0°, length 95 mm (64301 A)
- Diameter 2.7 mm, 25°, length 190 mm (64018 BS) Sheath 14,5 Fr. (67075 CC), biopsy forceps (67161 Z)
- Diameter 3 mm, triangular, 30°, length 140 mm (27030 B) including working channel and valves, biopsy forceps, diameter 1 mm (27071 ZJ)
- Diameter 4 mm, 25°, length 180 mm (64200 BW) sheath including valves (26181 HL).

Endovideo cameras or reflex cameras for slides can be used for documentation. The video camera works with the normal light of the light source used for endoscopic examination. In addition the examiner definitely knows the contents of the film he is documenting. The positive slide camera requires a flash generator and the contents of the film is only known after processing. At this time slides represent the maximum quality achievable.

After the examination is finished and the endoscope removed an antibiotic should be instilled into the pleuroperitoneal cavity. Serosa, muscles and skin are sutured in single or double layer with a U-type pattern. The patients are controlled until the first movements appear.

2.5.2 Non Invasive Endoscopic Techniques (Tracheoscopy, Pulmonoscopy, Oesophagoscopy, Gastrosocopy)

Endoscopic examination of the trachea, oesophagus and stomach can be performed in small to mid size (5 kg BM) reptiles using the rigid scopes listed above. To examine larger animals a flexible scope is preferred, for example the 5 mm, 55 cm length (600001 VB). In snakes, because of their elongated topographic anatomy and the unicameral lung design it is also possible to use extra long rigid endoscopes, especially for scientific purposes. The examination of the trachea, lungs, oesophagus or stomach in reptiles requires anesthesia. The patients are placed in dorsal or ventral recumbancy on a vacuum pillow. The head and neck should be straightened. The mouth, especially in cases where flexible scopes are used, should be fixed open.

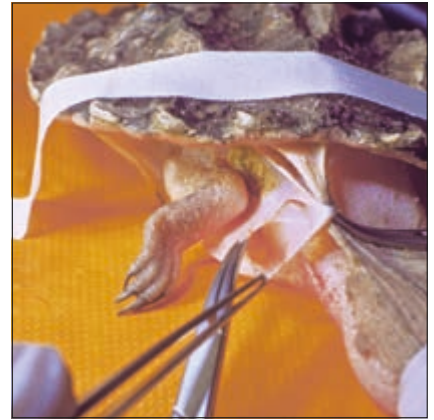


6 Endoscopic examination in the field.

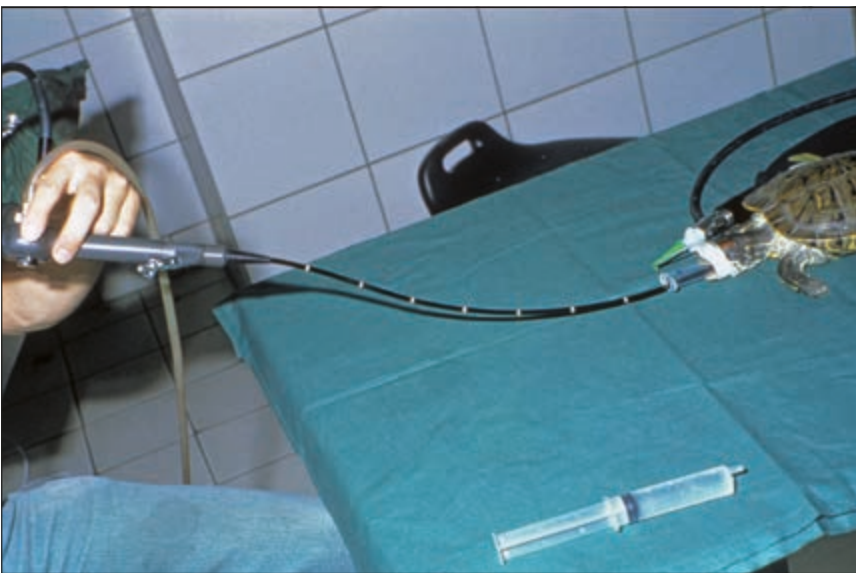Examination of free ranging monitors (*Varanus gouldii*) in Australia, endovideo equipment for documentation.

In cases of oesophagoscopy or gastroscopy the endoscope should be forwarded slowly and carefully. The permanent insufflation permits visualisation of the widening oesophagus. If the scope enters the stomach care must be taken not to over insufflate. Flexible endoscopes allow the front lens to turn in three directions whereas rigid scopes with angled front lenses allow the field of view to vary by rotating the scope. If foreign bodies are to be extracted care should be taken for sharp edges (e.g. fish hooks) not to be directed towards the oesophageal wall. If the chosen rigid endoscope is too short, for example in long neck turtles, a lateral transoesophageal approach on the right side of the neck is possible.

Endoscopic examination of the respiratory tract requires endoscopes smaller in diameter than the trachea. The introduction via the glottis is easy in reptiles because of the lack of an epiglottis. In crocodiles there is a septum rostral to the glottis which needs to be lifted to allow access to the glottis. While the scope is moved forward in the tracheal lumen, care must be taken not to touch the mucosal surface. The tracheal mucosa is very fragile and tends to irritate easily if manipulated. In addition most of the tracheal rings are closed in reptiles and therefore the lumen is not flexible. In snakes and lizards the scope can be forwarded through the bifurcation into the lumen of the lungs. Primitive reptiles like most of the lizards and the snakes have unicameral lungs that can be easily examined and biopsied. In monitors and chelonians the lungs are multicameral and only the two main bronchi may be examined. In addition the bronchi in chelonians curve dorsally to enter the lungs. Therefore only flexible scopes are recommended.



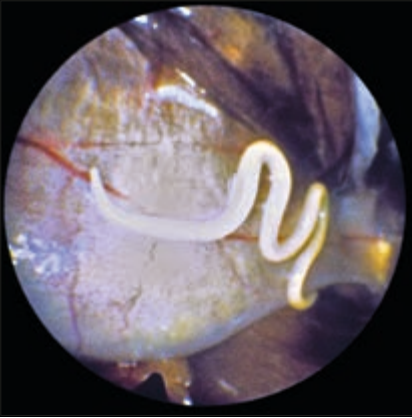8 Gastroscopy in a turtle.
(*Mata mata*), lateral transoesophageal approach.



7 Gastroscopy in a turtle.
Read Eared Silder (*Pseudemys scripta elegans*), 5 mm flexible endoscope.

2.6 Endoscopic Examination of the Pleuroperitoneal Cavity

▼ Pathological Alterations

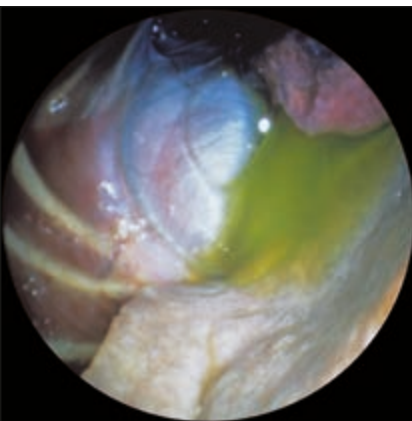


9 Infestation with *Filaria* spp.
Grey monitor (*Varanus griseus*)
view to the caudal part of the coelom

Left and center:
grey serosa covering the colon

Right:
cloaca, on the surface of the serosa a *Filaria* spp. moving slowly away from the light source, endoscopic removal using forceps.

▼ Pathological Alterations



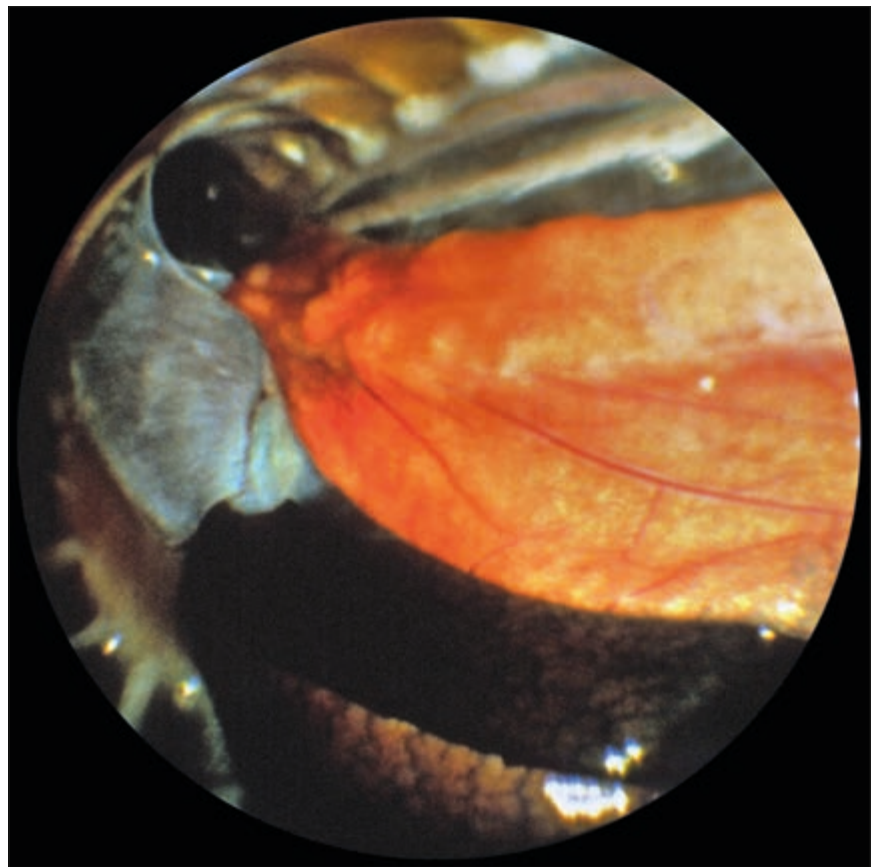
10 Ascites.
Green Iguana (*Iguana iguana*).

Ventral: altered grey liver
(bile duct carcinoma)
with irregular shape and surface,
left: rib cage,
top left: blue-red pericardium,
top right: red lung
center: green coloured ascitic fluid.

The endoscopic examination of the pleuroperitoneal cavity begins with the cranial aspects of the coelom, heart, lungs, liver, spleen, serosal surface and large vessels (Aorta). Following the aorta caudally, the intestines, gonadal structures, kidneys and bladder are examined. Turning the endoscope ventrally and cranially, the intestines and the liver are visible. While removing the scope, the fat bodies are examined. To follow this route of examination prevents the surgeon from overlooking important structures. This route was established for the lizard, primarily. The examiner has to match it to the patient and the indication for the endoscopic examination.

2.6.1 The Pleuroperitoneal Cavity

▼ Normal Endoscopic Appearance

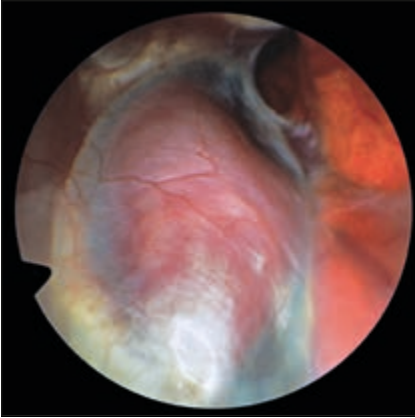


11 Pleuroperitoneal cavity, cranial aspect.

Green Iguana (*Iguana iguana*).
Center: red deflated left lung with longitudinal superficial vessels,
ventral brown left lobe of the liver with sharp edges,
left: blue-red pericardium,
top: vertebral column and rib cage.

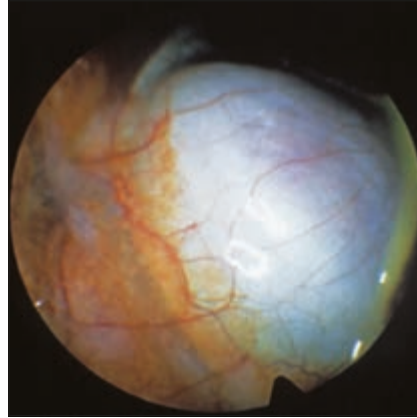
2.6.2 Heart

▼ Normal Endoscopic Appearance



12 Pericardium and heart.

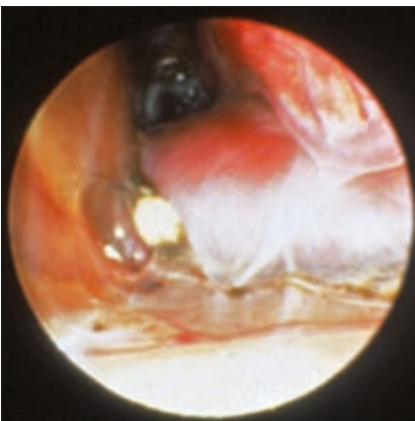Green Iguana (*Iguana iguana*)
the thin, blue pericardium is translucent with superficial vessels, the red heart is displayed through the pericardium, *right*: the red lung.



13 Pericardium and ventral fixation.

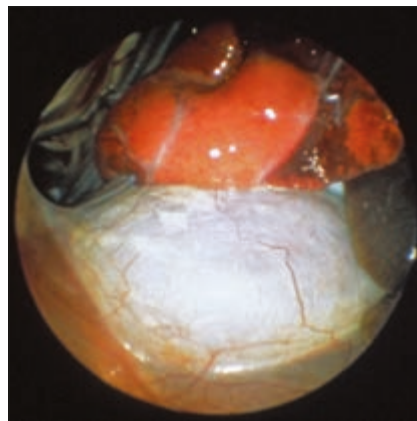Shingle Back (*Trachydosaurus rugosus*)
in most of the lizards the pericardium is fixed to the sternum ventrally by soft tissue (not in monitors). The pericardium is more grey and less translucent in this species, *left*: attachment to the sternum by orange coloured soft tissue with distinct vascularisation.

▼ Pathological Alterations



14 Abscess at the base of the heart.

Uromastix (*Uromastix acanthinurus*)
center: Pericardium,
right: lung
left: rib cage on the left lateral aspect of the pericardium a large, yellow abscess is visible, endoscopic biopsy and microbiology revealed it to be caused by *Salmonella* spp.

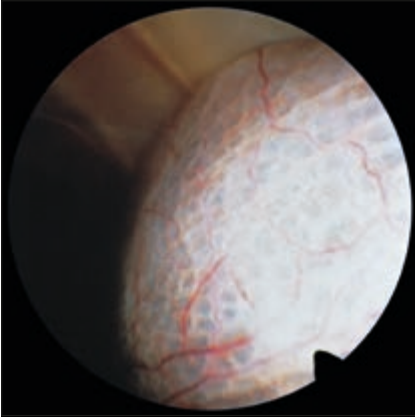


15 Visceral gout.

Green iguana (*Iguana iguana*)
center: the grey pericardium is not translucent (compare to fig. 12), white flakes of uric acid are deposited subserosally in the pericardium, they can not be removed endoscopically.

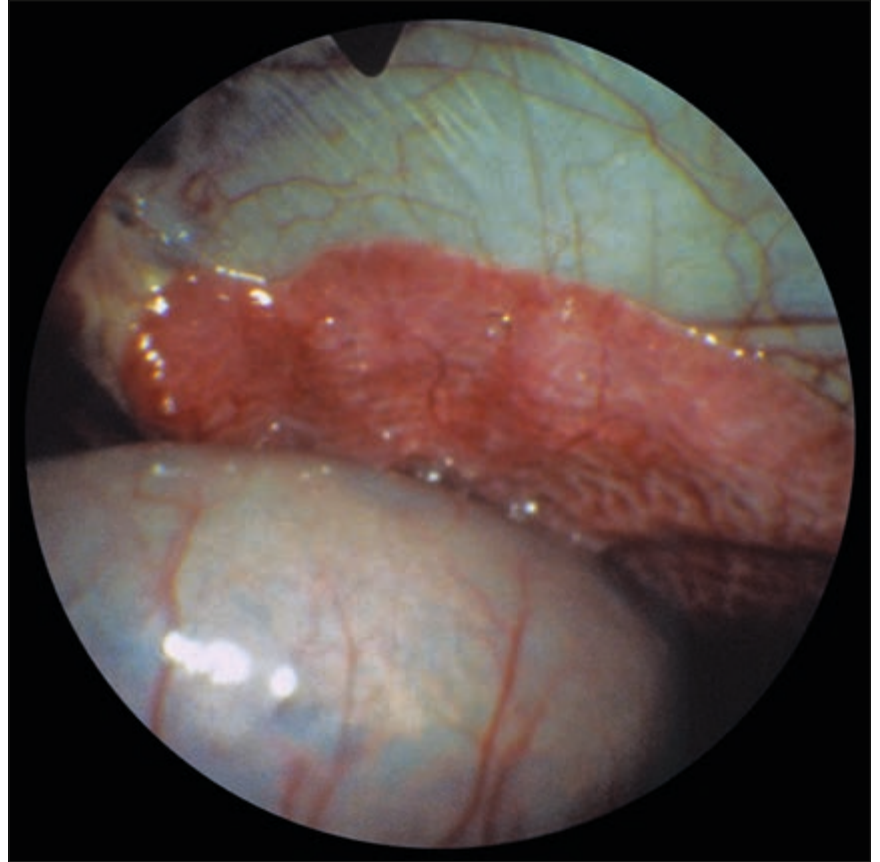
2.6.3 Lungs

▼ Normal Endoscopic Appearance



16 Insufflated unicameral lung of a lizard.

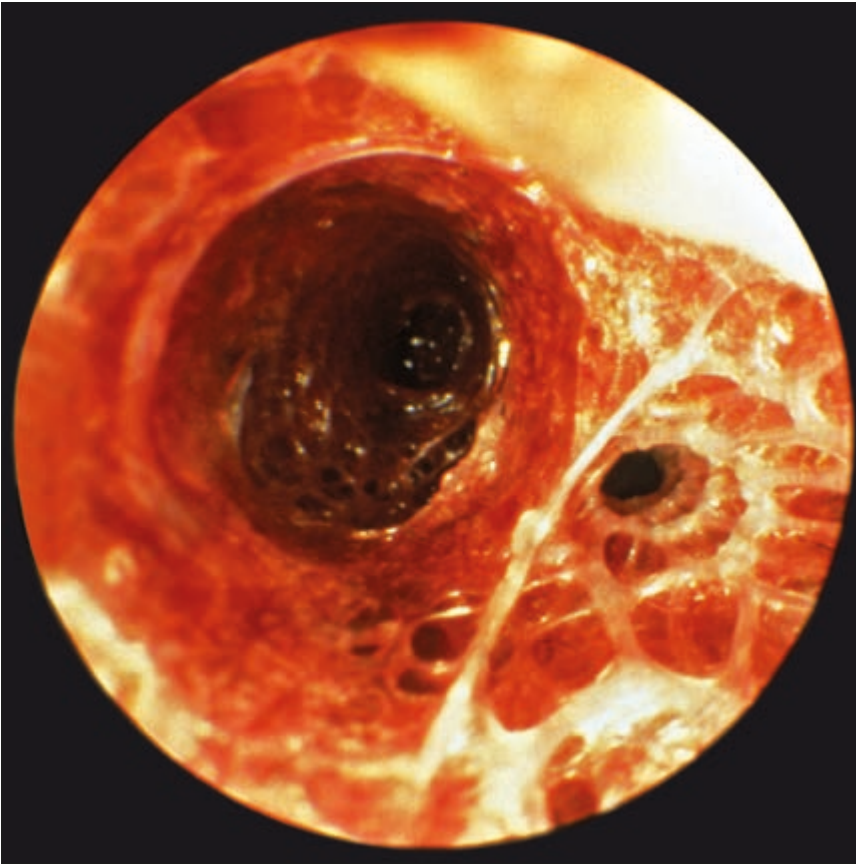
Green Iguana (*Iguana iguana*).
The thin walled insufflated lung displays a typical honey comb like structure, the faveoli are surrounded by thin walls of muscles which enables the lung to insufflate during endoscopic examination under insufflation, large vessels run subserosally over the surface.



17 Deflated multicameral lung of a turtle. (*Dermatemys marnii*).

Ventral: the grey colon with distinct vessels,
top: the carapace covered by blue grey serosa,
center: the left, deflated red lung, honey comb like appearance (multicameral structure)
the *septum horizontale* is attached to the lung's surface and translucent.
(compare to the unicameral normal lung in fig. 9).

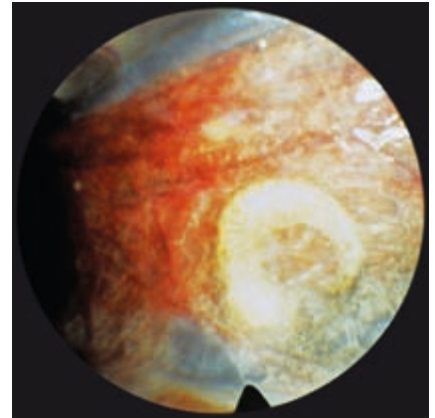
▼ Pathological Alterations



18 Perforation of the lung.

Monitor (*Varanus varius*).

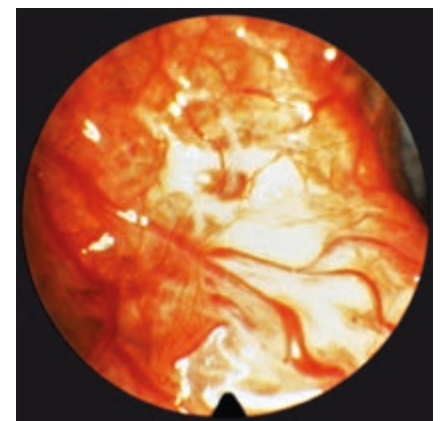
The unintentional perforation of the lung can be a complication during introduction of the endoscope if the chosen point of entry is too far cranial, especially in monitors, because the lungs are fixed to the *septum postpulmonale*. It is important to control for bleeding while removing the scope slowly. Haemostatics can be instilled through the working channel. Parasites could be removed via an intentional entrance (compare fig. 18).



19 Infestation with pentastomes.

Goulds Monitor (*Varanus gouldii*).

Pentastomes are common parasites, especially in monitors, the yellow, curved parasite is visible through the thin wall of the lung, it is possible to incise the lung and extract the parasite endoscopically, afterwards the lung is sutured.



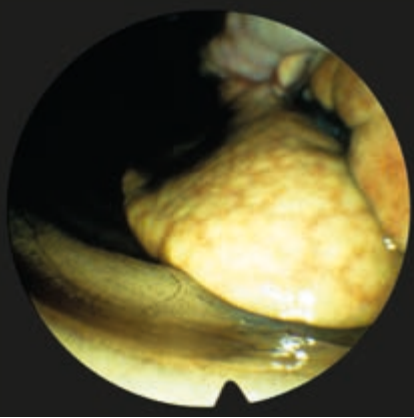
20 Abscesses in the lung.

Green Iguana (*Iguana iguana*).

In the center and ventral aspect, yellow alterations with a central dens are visible, biopsy and microbiology revealed this to be a infection with *Morganella morganii*, response after treatment can be examined endoscopically.

2.6.4 Liver

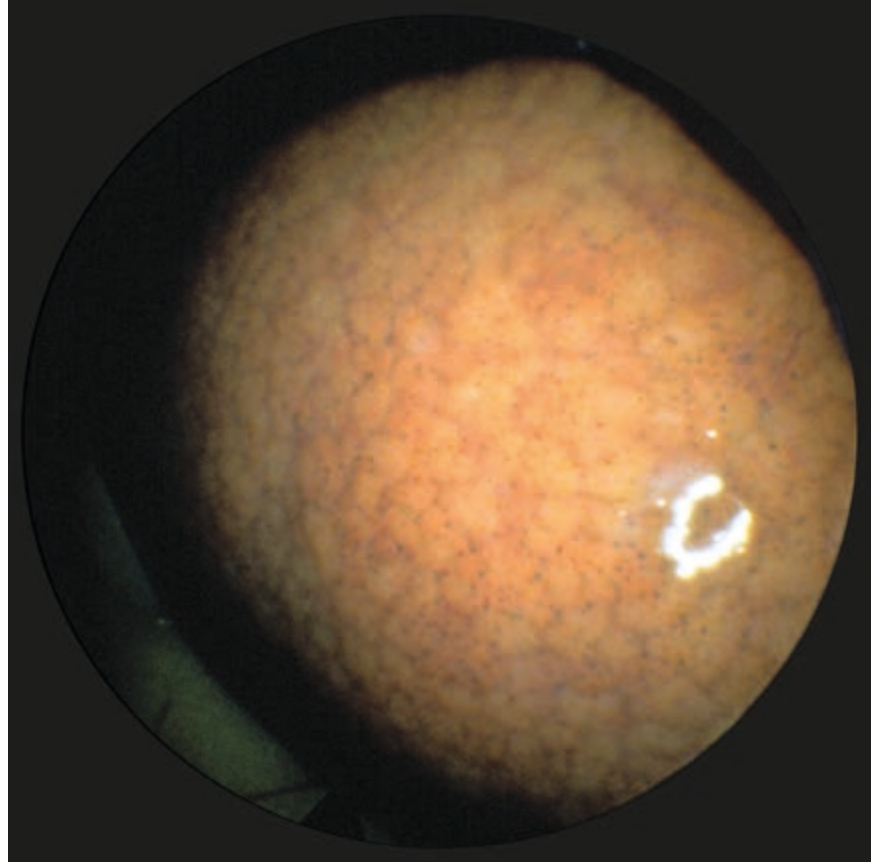
▼ Pathological Alterations



21 Fatty degeneration.

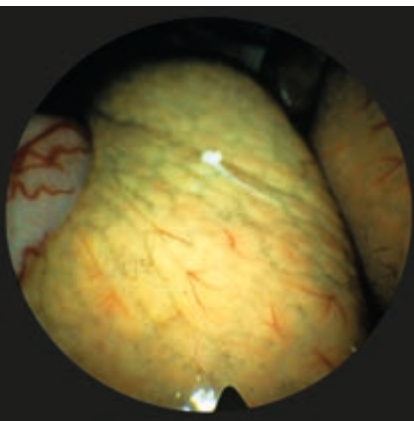
Shingle Back (*Trachydosaurus rugosus*)
 center: liver, ventral: ribs, top: stomach.
 This is a common endoscopic diagnosis in captive reptiles, especially in carnivorous species like monitors, the liver is dark to bright yellow in colouration, the surface is irregular and the borders are rounded. It was never found in wild caught animals, independent from their nutritional condition.

▼ Normal Endoscopic Appearance



23 Liver.

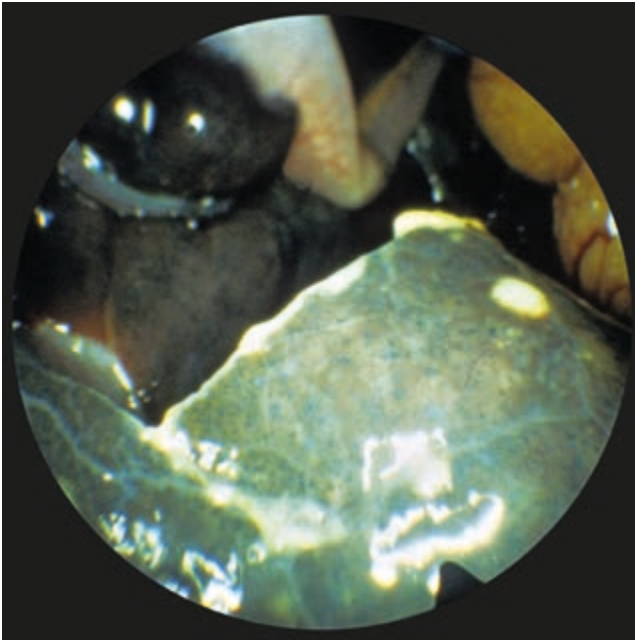
Green Iguana (*Iguana iguana*)
 the liver is brown, with smooth serosal surface and sharp borders, typical for reptiles are the melanomacrophages seen in a black, honey comb like pattern.



22 Hepatitis.

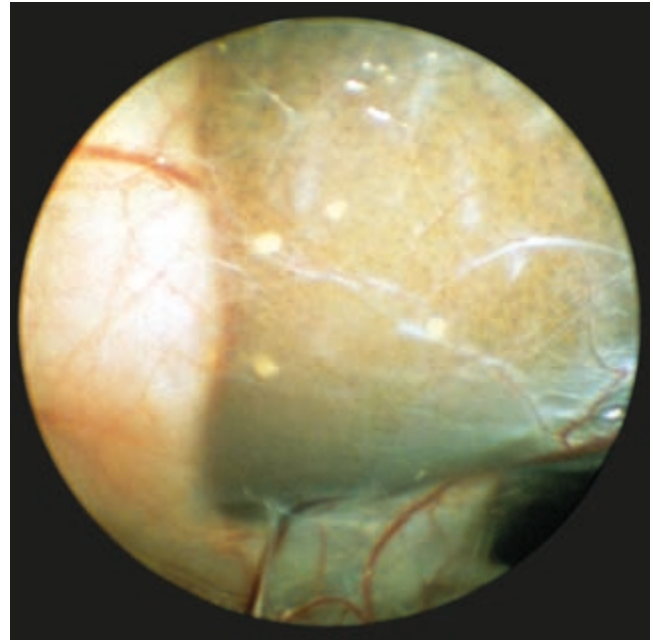Turtle (*Dermatemys marnii*)
 the yellow, fatty liver displays distinct large superficial vessels, the inflammation can be infectious, or non-infectious as in this case (deposits of uric acid).

▼ Pathological Alterations



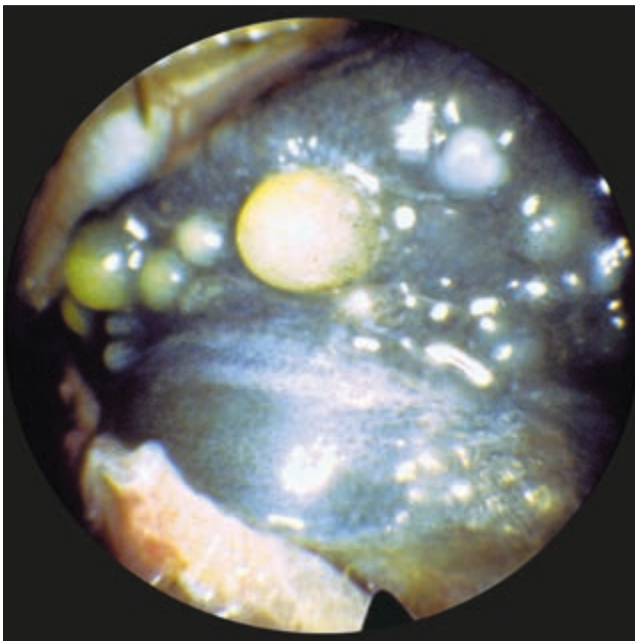
24 Liver Abscesses.

Herman's Tortoise (*Testudo hermanni*).
Center and ventral: liver, grey colouration, irregular borders with inflammation, on the dorsal aspect a distinct yellow abscess, biopsy and microbiology revealed a *Salmonella* sp. infection, dorsal white stomach, right dorsal yellow ovarian follicles.



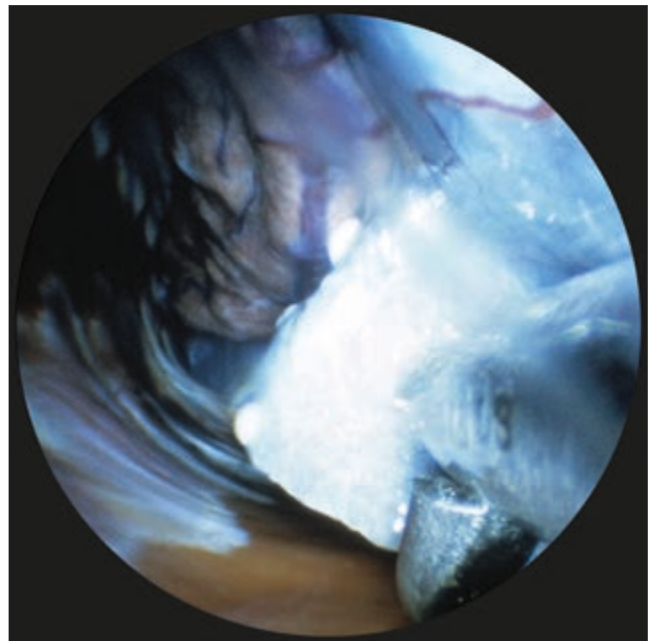
25 Amoebiasis.

Pacific Monitor (*Varanus indicus*).
Left to center: brown liver with multiple white focal necrosis, typically for infestation with *Entamoeba* sp., examination of fecal samples are recommended to verify the diagnosis.



26 Liver cysts.

Bearded Lizard (*Amphibolurus vitticeps*).
 The liver is covered by a dark serosa in some species, the yellow bubbles are subserosal liver cysts, they can be punctured and evacuated endoscopically.

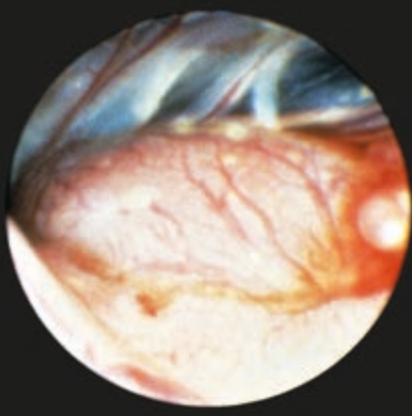


27 Liver carcinoma.

Green Iguana (*Iguana iguana*).
Ventral and left: sternum and rib cage, top left: deflated pink left lung, *center:* blue white liver with irregular surface and white bumps, *right:* endoscopic biopsy forceps introduced, further histological examination revealed this case to be a liver carcinoma.

2.6.5 Spleen

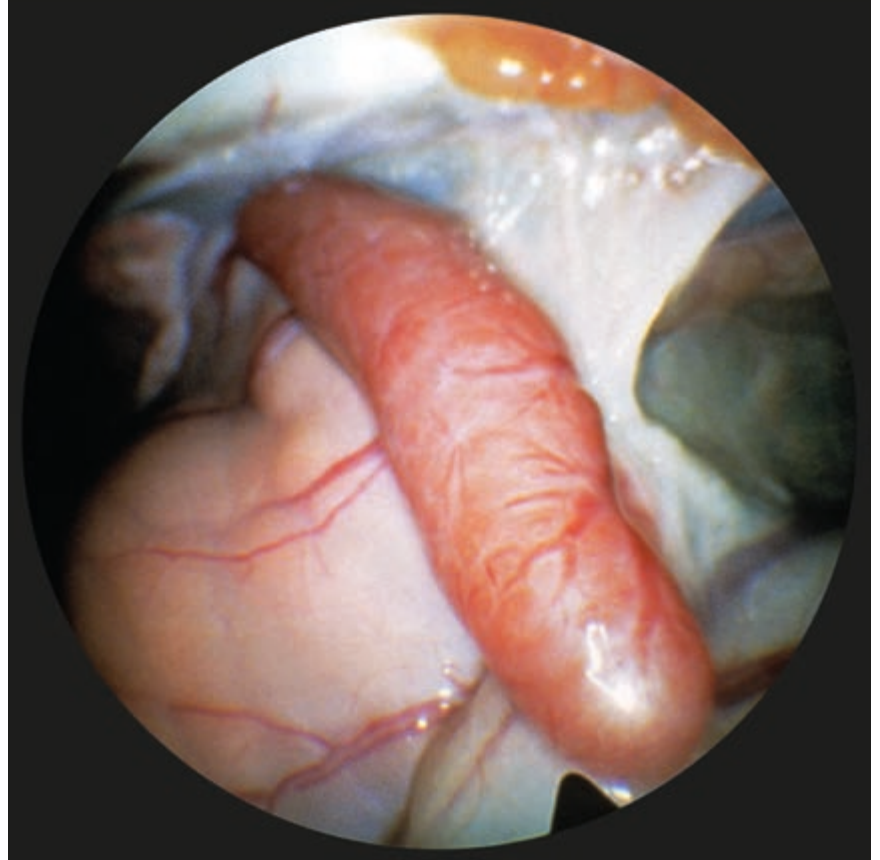
▼ Pathological Alterations



28 Amoebiasis.

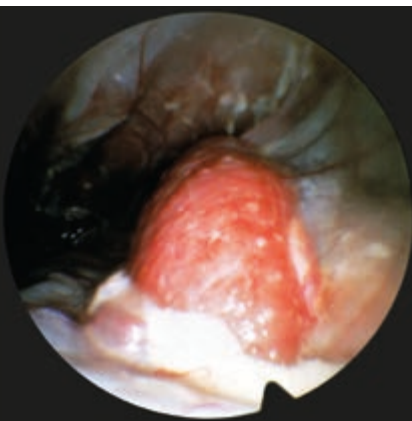Pacific Monitor (*Varanus indicus*).
The red bean shaped spleen displays multiple yellow button like necrotic areas caused by *Entamoeba* sp. infection, examination of fecal samples are recommended to verify the diagnosis.

▼ Normal Endoscopic Appearance



30 Spleen.

Green Iguana (*Iguana iguana*).
The spleen is laying dorsal on the intestines just caudal of the liver, the shape varies inter-specifically, bean shaped in chelonians, snakes and Monitors, cigar shaped in Iguanids. The colour is red to red brown, the surface smooth, like in this Iguana to cauliflower like in some monitors, distinct superficial vessel are seen.

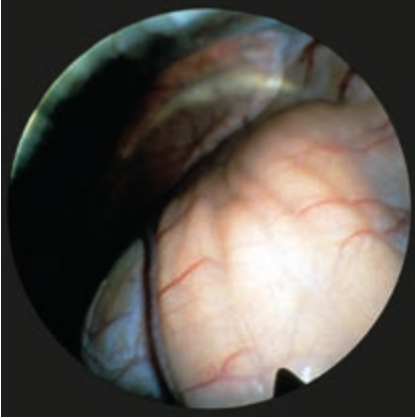

29 Visceral Gout.

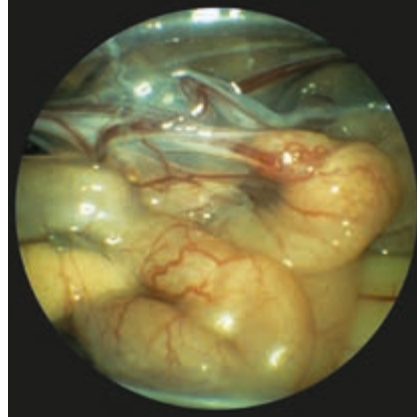
Philipin Monitor (*Varanus cumminghii*).
The bean shaped red spleen displays multiple irregular subserosal white flakes, biopsy revealed them to be deposits of uric acid.

2.6.6 Stomach and Intestines

▼ Normal Endoscopic Appearance

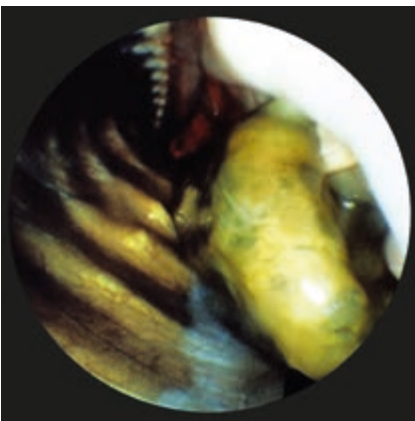


31 Stomach.
Green Iguana (*Iguana iguana*).
Center to right ventral: the white stomach displays typical longitudinal folds and is covered by the translucent mesentery, distinct superficial vessels running in the serosa.

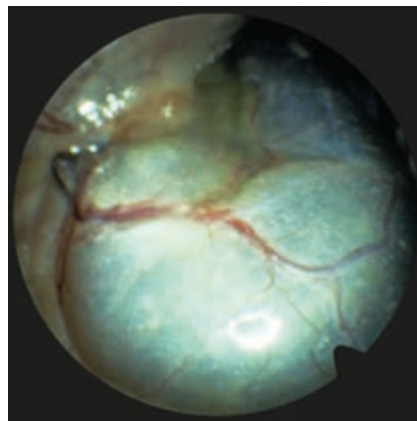


32 Small and large intestines.
Gould's Monitor (*Varanus gouldii*).
Mid left: the grey white stomach proceeds into the short small and large intestines which are more yellow pink coloured, the large vessels run through the mesenterium.

▼ Pathological Alterations



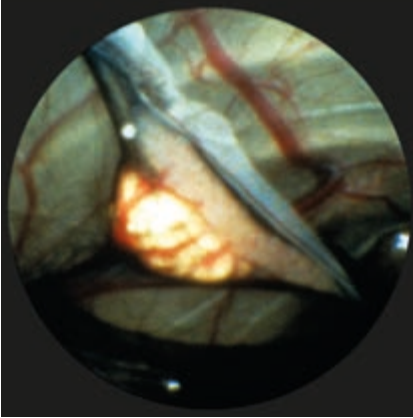
33 Obstipation (Ileus).
Shingle Back (*Trachydosaurus rugosus*).
Left: rib cage ventral: abdominal wall and serosa, dorsal: vertebral column, center: green yellow, irregular surface the colon, the colon wall is closely applied to the dehydrated ingesta.



34 Paralytic Ileus, Ascites.
Green Iguana, (*Iguana iguana*).
Center and ventral: the paralyzed enlarged, blue colon, center dorsal: yellow green ascites, in this case caused by ingesting of unwashed sharp stone gravels.

2.6.7 Gonads

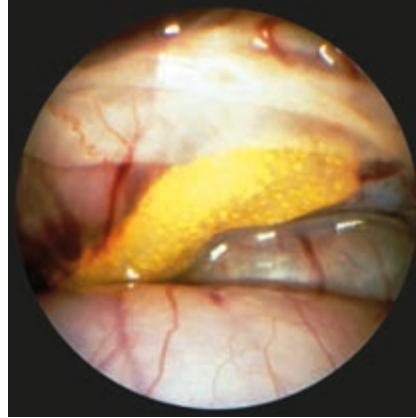▼ Normal Endoscopic Appearance



35 Ovary, juvenile.

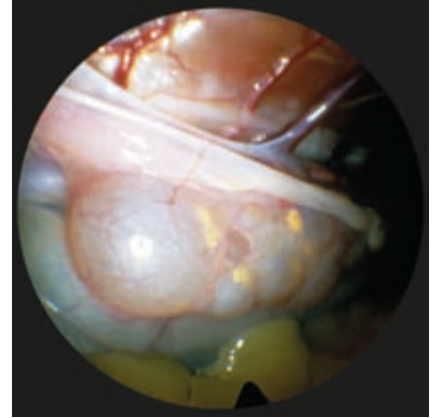
Gould's Monitor (*Varanus gouldii*) endoscopic examination permits the identification of the sex even in juvenile reptiles (in this case 30g BM, 3 months old)

dorsal: grey white peritoneal cavity
center left: yellow adrenal gland with distinct superficial vessels, attached to the right the ovary, light pink, cigar shaped, attached to the right the blue, translucent oviduct, cranial to the adrenal gland the dark blue aorta.



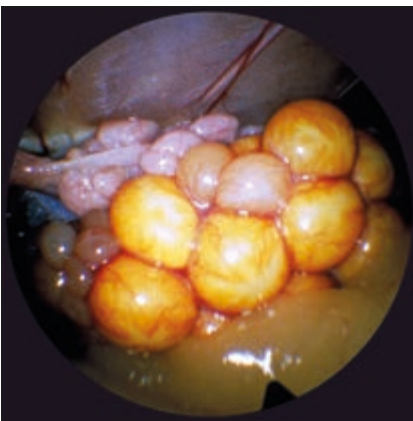36 Ovary, subadult.

Long necked turtle (*Chelodina longicollis*)
center: the yellow flat ovary with bright yellow primary follicles is displayed,
dorsal: the white oviduct runs from the left to the right, *ventral*: intestinal loops are visible.



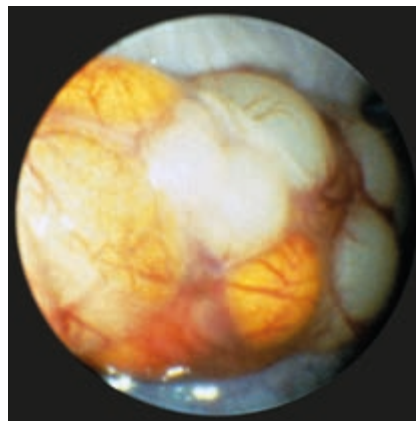
37 Ovary, adult, previtellogenic follicles.

Salvator's Monitor (*Varanus salvator*)
center: the pink grey previtellogenic follicles are displayed, small vessels running superficially, *ventral*: yellow fat body, dorsal to the ovary the white pink oviduct, *dorsal*: one artery crossing from the aorta to the lateral body wall.



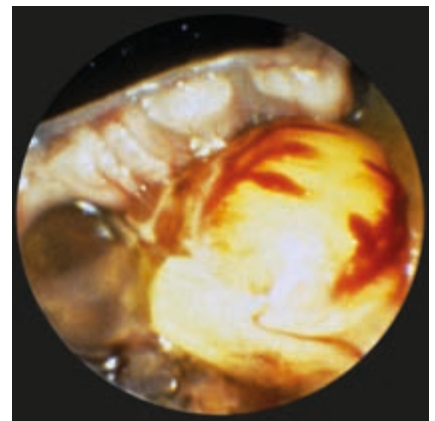
38 Ovary, adult, vitellogenic follicles.

Green Iguana (*Iguana iguana*). The large yellow vitellogenic follicles are covered by distinct superficial vessels, on the left are some small previtellogenic follicles with amber colouration visible, dorsal to the ovary the pink, curved oviduct is displayed, ventral to the ovary the yellow, flat fat body is visible.



39 Ovary, Corpora lutea.

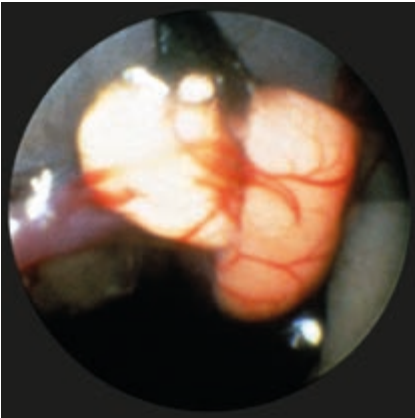
Blue tongue scink (*Tiliqua scincoides*). Corpora lutea display as bright yellow buttons with central dens in between the white previtellogenic follicles, which are covered by distinct superficial vessels.



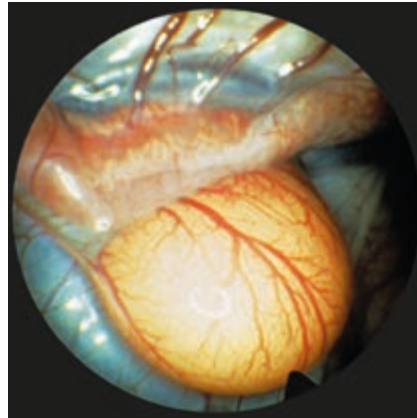
40 Follicles in resorption.

Chuckwalla (*Sauromalus obesus*). Reptiles are able to resorb even large vitellogenic follicles. The large yellow vitellogenic follicle is covered with broad vessels without distinct borders, *dorsal*: pink coloured oviduct.

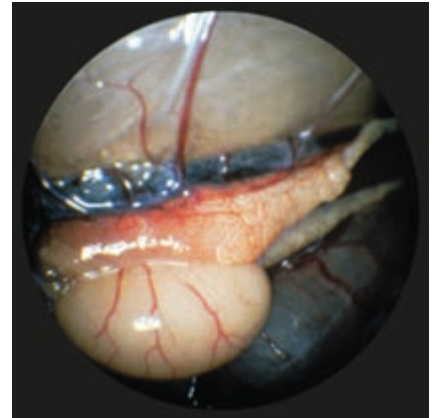▼ Normal Endoscopic Appearance



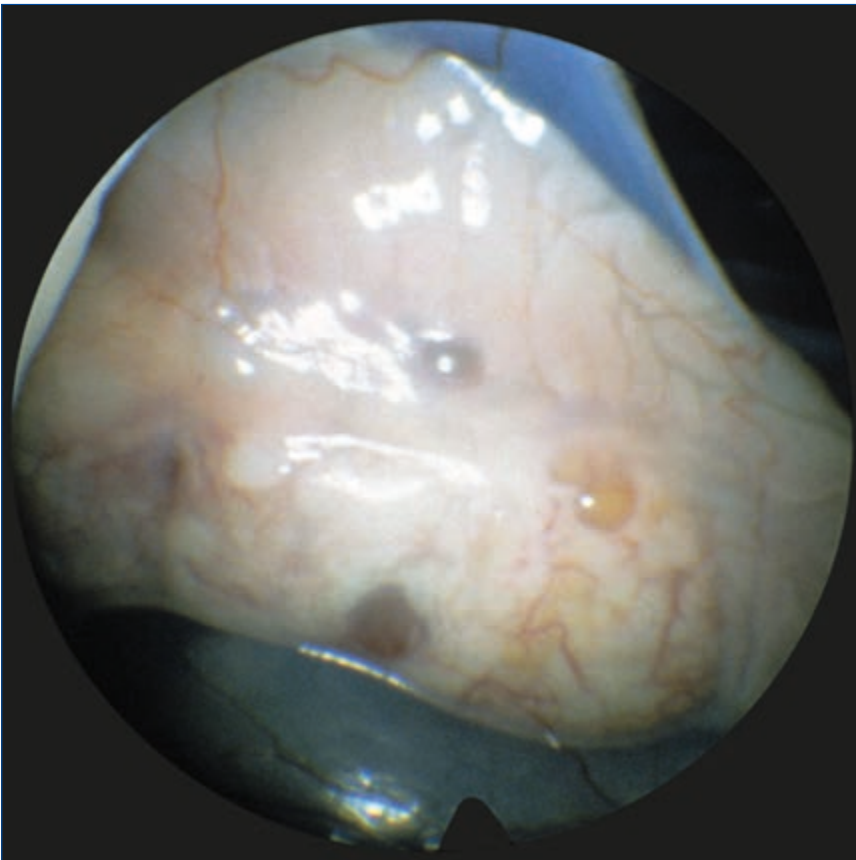
41 Testicle, juvenile.
Gould's Monitor (*Varanus gouldii*).
Mid left: the yellow adrenal gland with distinct superficial vessels, *mid right:* the bean shaped light pink coloured testicle with small superficial vessels.



42 Testicle, adult.
Shingle back, (*Trachydosaurus rugosus*).
The yellow testicle is covered by sagittal superficial vessels, dorsal the vas deferens runs caudally.



43 Testicle, adult, sexual active.
Green Iguana (*Iguana iguana*).
The colour of the testicle is species specific, in Iguanas it is white. The large testicle shows the typical sagittal superficial vessels, dorsal to the testicle the enlarged epididymis and the Vas deferens running caudally is displayed, ventral to the left vas deferens the right one can be seen.

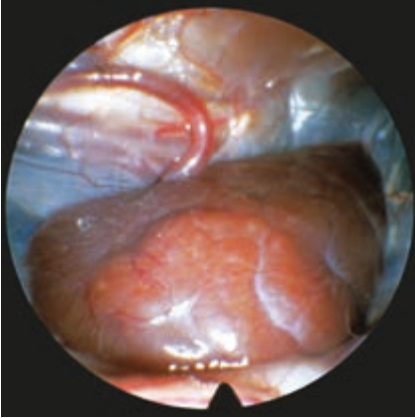

◀ Pathological Alterations

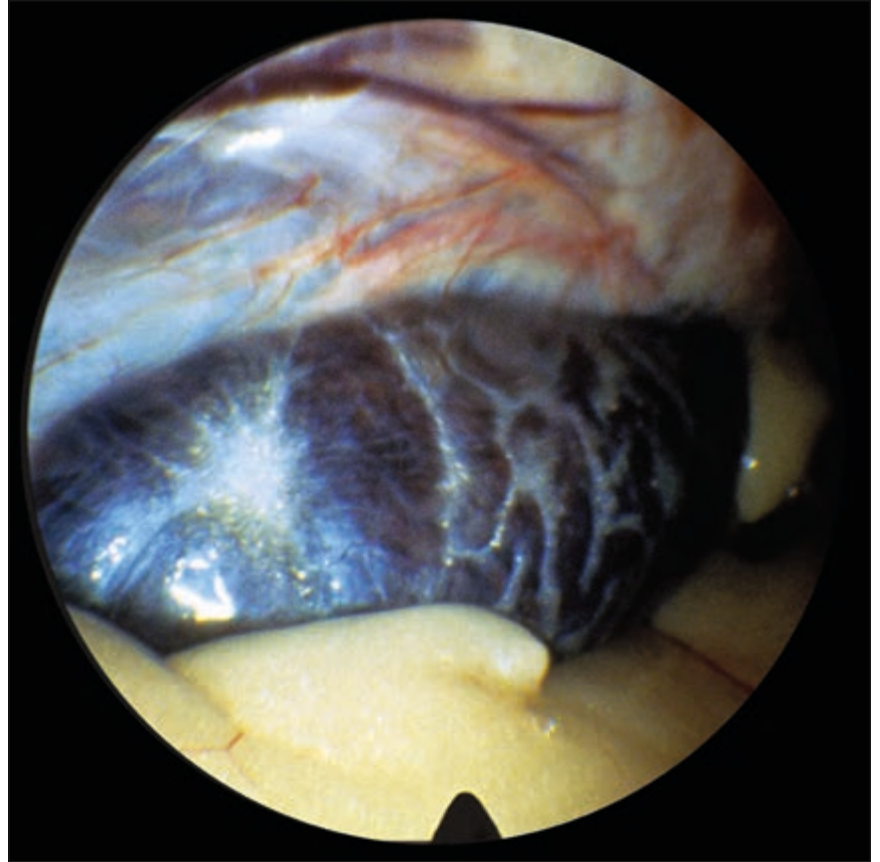
44 Yolk depositions in the ovary.
Pacific Monitor (*Varanus indicus*).
Ventral: the degenerated ovary, *dorsal:* the white oviduct and the blue mesoviduct are displayed, the ovary contains disposed white yolk material and only a few amber coloured follicles.

2.6.8 Kidneys

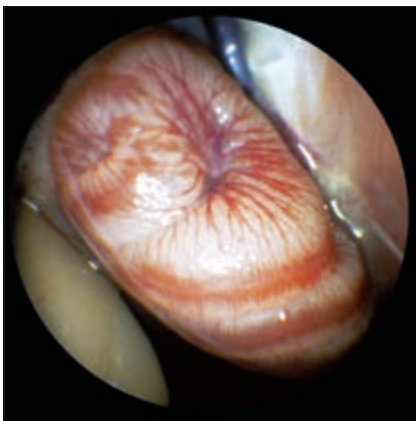
▼ Normal Endoscopic Appearance



45 Kidney.
Philippine Monitor (*Varanus cumminghii*).
The red brown kidney is built of slices like segments.

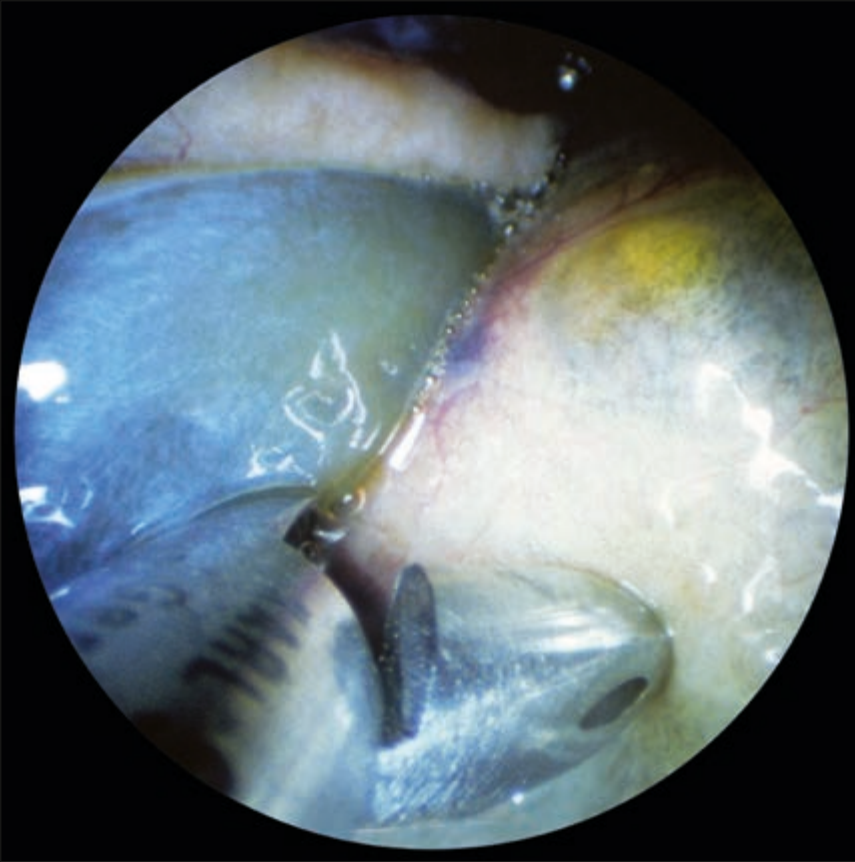


47 Kidney, colour variations.
Gila monster (*Heloderma suspectum*)
in some species, especially in older individuals the colour of the kidney can turn into brown black, the white tissue induration is also typical for older animals.



46 Kidney, sexual segment.
Pacific Monitor (*Varanus indicus*)
the sexual segment of the kidney is found in some reptile genera, it enlarges in sexually active individuals and displays as white parts within the parenchyma, the kidney shows a red white alternating pattern, in these genera no epididymis is verifiable.

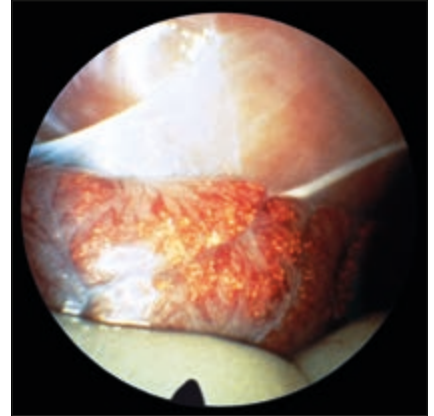
▼ Pathological Alterations



48 Tumor (adenoma).

Green Iguana (*Iguana iguana*).

Left: the blue rectum, *right:* the kidney displays as a grey white enlarged body with superficial yellow dots of uric acid, *ventral:* the biopsy forceps are introduced to extract a sample.



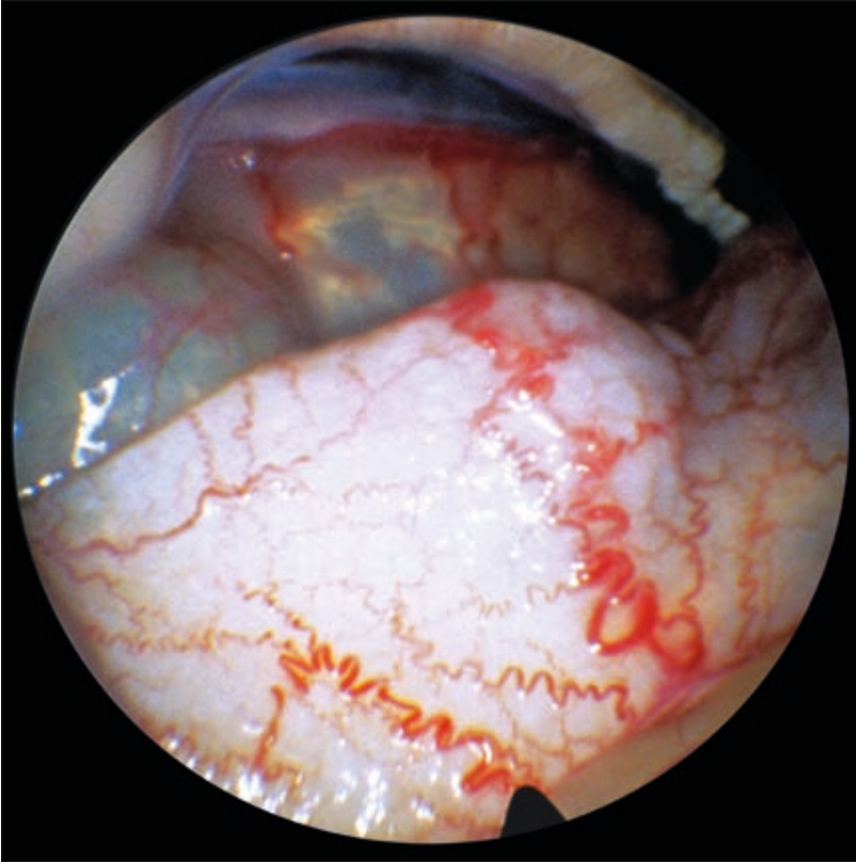
49 Gout.

Pacific Monitor (*Varanus indicus*).

Deposits of uric acid display as white or golden coloured stripes or confluent dots, histological examination or direct microscopy of endoscopic biopsies will verify the diagnosis.

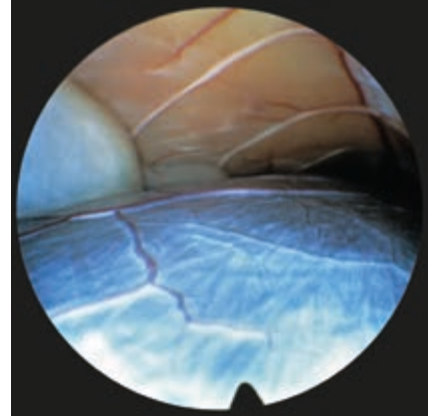
2.6.9 Bladder

▼ Normal Endoscopic Appearance



50 Bladder, empty.

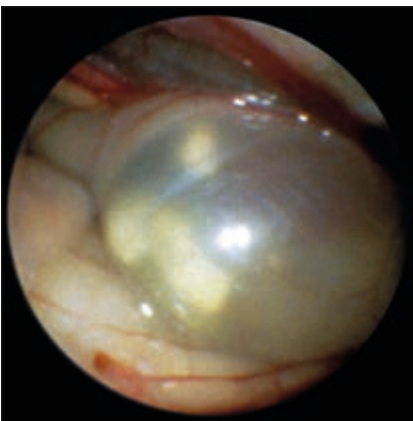
Green Iguana (*Iguana iguana*).
The empty bladder displays as a white flat body with distinct superficial twisted vessels, *dorsal*: fluid filled rectum.



51 Bladder, filled.

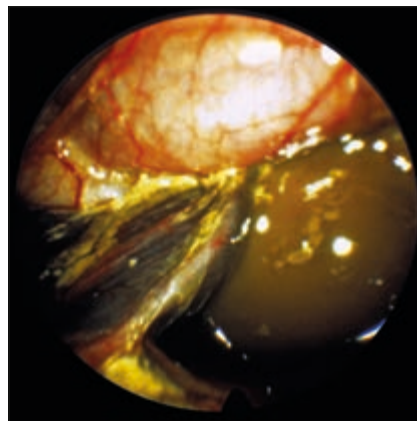
Green Iguana (*Iguana iguana*)
the bladder is a blue colour, the superficial vessels are elongated, *dorsal*: bodywall, the filled bladder can occupy some space in the caudal body cavity, care must be taken not to perforate the bladder with the endoscope (scope directed cranially while introducing).

▼ Pathological Alterations



52 Bladder, uric acid sludge.

Water Monitor (*Varanus mertensi*).
Within the filled bladder yellow flakes of uric acid can be demonstrated.

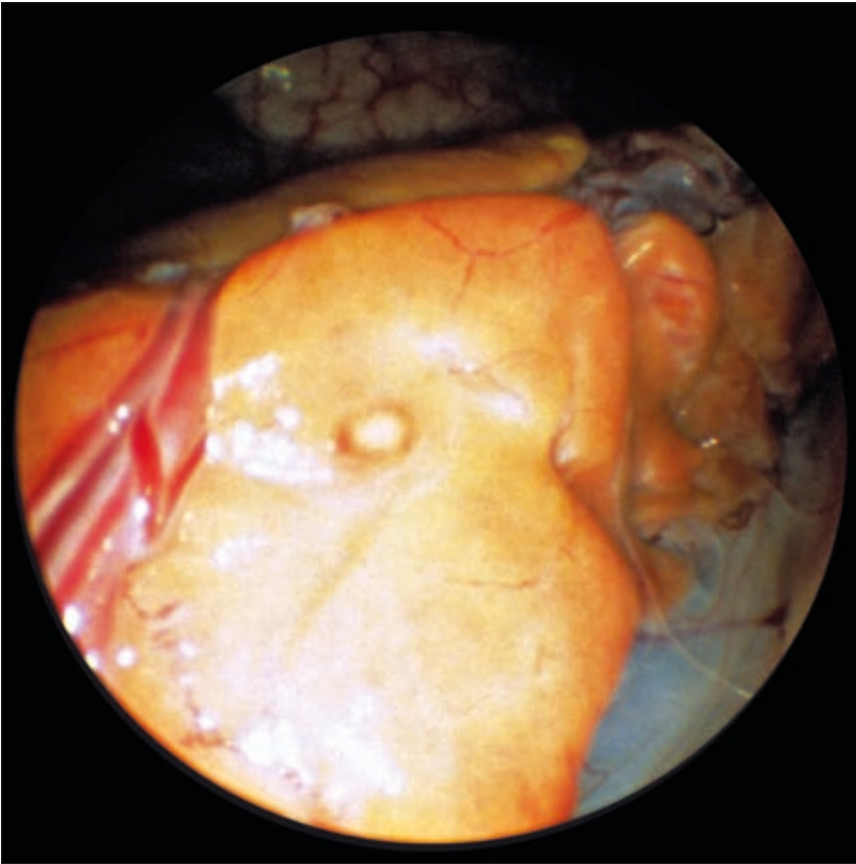


53 Bladder, ruptured.

Marginated tortoise (*Testudo marginata*)
green urine and uric acid sludge (*ventral right*) is dispersed over the entire body cavity, left the caudal part of the left liver lobe is a dark grey colour with distinct superficial vessels (hepatitis), *dorsal*: white stomach, tortoise dropped while being handled by the owner is a common reason, therapy: multiple rinses can be performed through the scopes working channel.

2.6.10 Fat Bodies

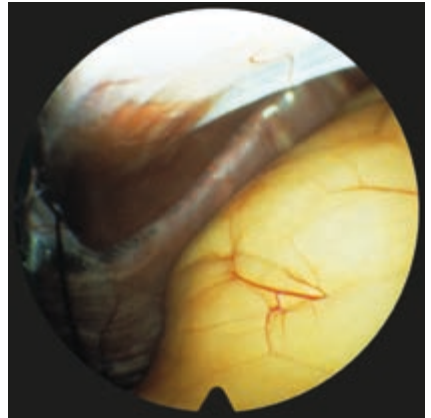▼ Pathological Alterations



54 Abscesses.

Pacific monitor (*Varanus indicus*)
within the orange coloured fat body is a yellow round abscess with hemorrhagic walls, endoscopic biopsy and microbiological examination revealed a bacterial infection (*E. coli*).

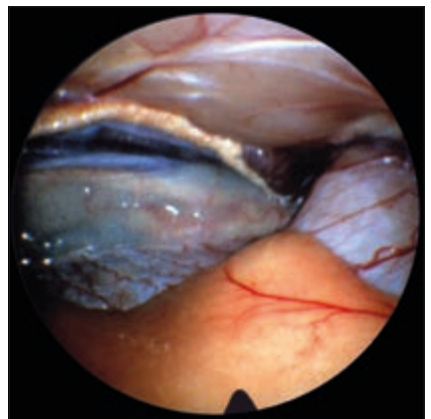
▼ Normal Endoscopic Appearance



55 Fat body, enlarging.

Monitor (*Varanus varius*)
growing fat bodies can occupy large parts of the coelomic cavity in lizards, they are characterized by yellow colour and lobulated structure with distinct vessels running over and between the lobes (right).

▼ Normal Endoscopic Appearance

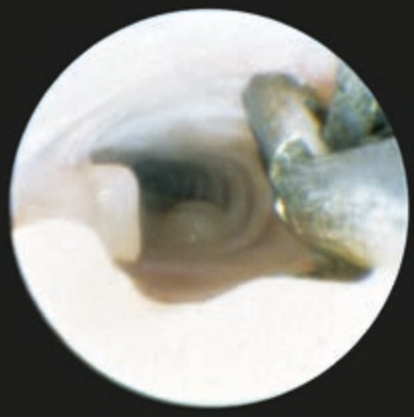

56 Fat body, in resorption.

Green Iguana (*Iguana iguana*).
In fasting periods the fat bodies are resorbed, the colour turns to orange pink (ventral), dorsal: body wall, left: green grey large intestine, blue aorta and white vas deferens, right: white bladder.

2.7 Non Invasive Endoscopy in Reptiles

▼ Normal Endoscopic Appearance



57 Tracheal mycobacteriosis.

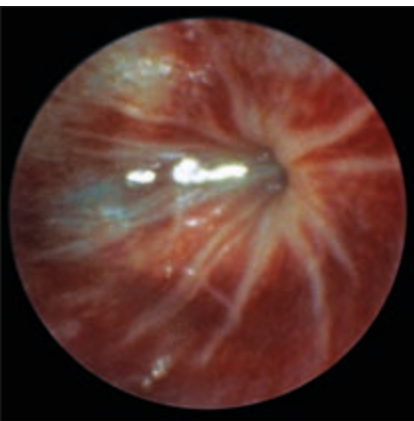
Boid snake (*Corallus caninus*).
Within the trachea multiple white nodules are visible, endoscopic biopsy (right) and direct Ziehl Nielsen staining revealed a mycobacterial infection.

2.7.1 Tracheoscopy, Pneumonoscopy (Fig. 57)

2.7.2 Oesophagoscopy, Gastroscopy (Fig. 58 + Fig. 59)

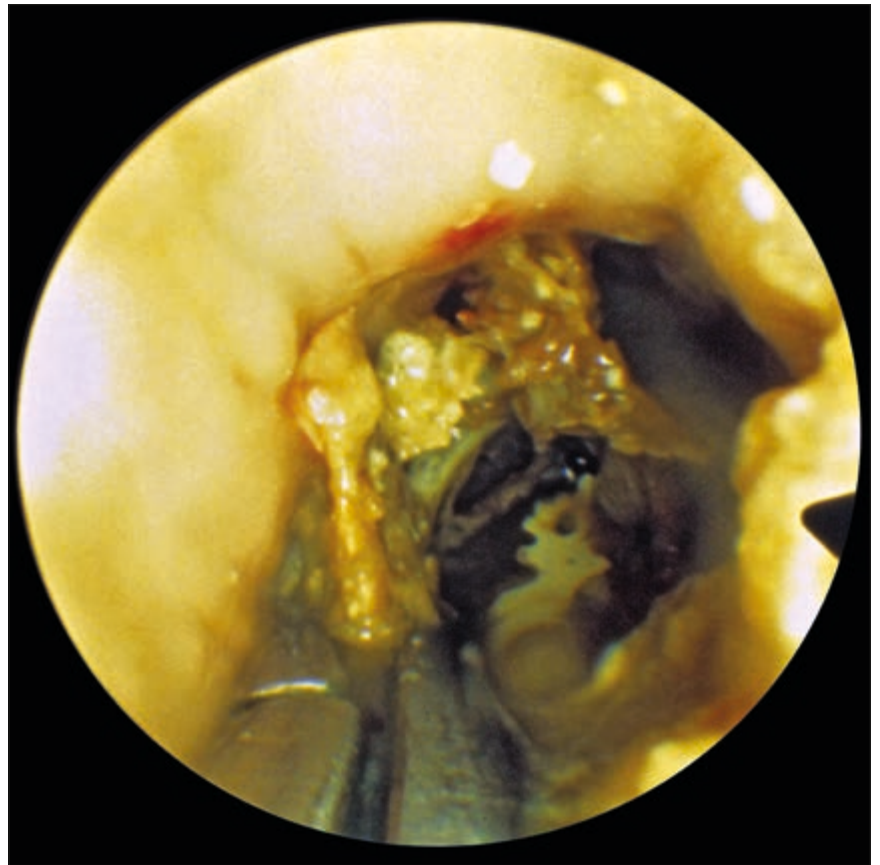▼ Pathological Alterations

▼ Normal Endoscopic Appearance



58 Oesophagoscopy.

Red Eared Slider
(*Pseudemys scripta elegans*)
the typical longitudinal red white stripes of the oesophageal wall are displayed.



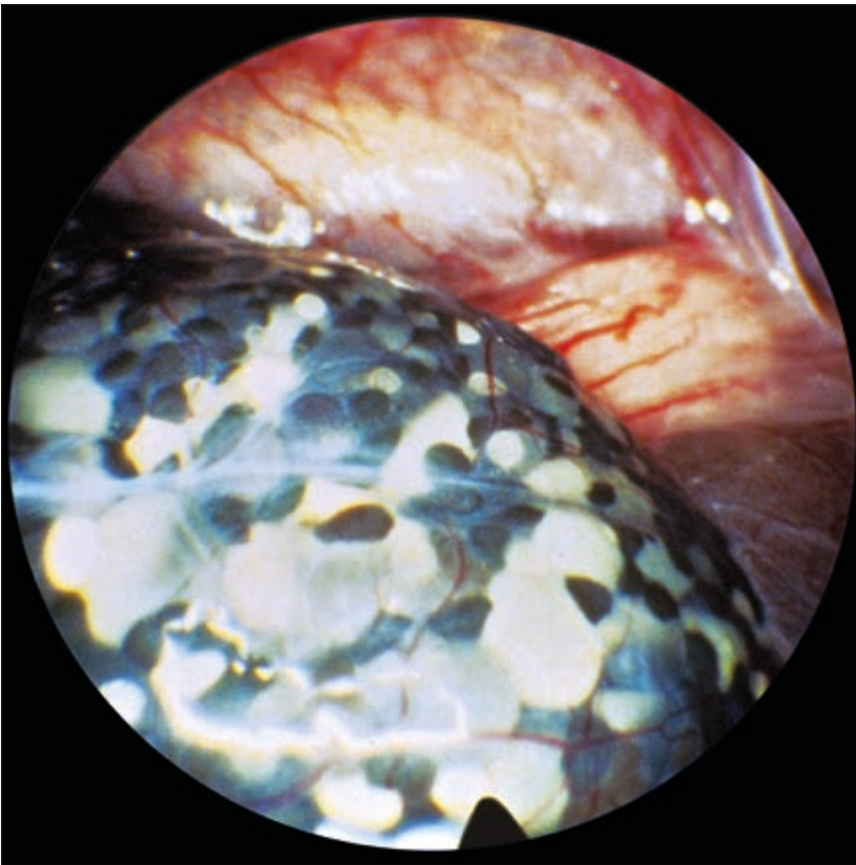
59 Gastric foreign body.

Turtle (*Mata mata*).
The endoscopic biopsy forceps (ventral) are introduced through the working channel to remove snail shells from the stomach.

2.8 Endoscopy in Amphibians

The principles of endoscopic techniques and diagnosis in amphibians are quite similar to the ones in lizards.

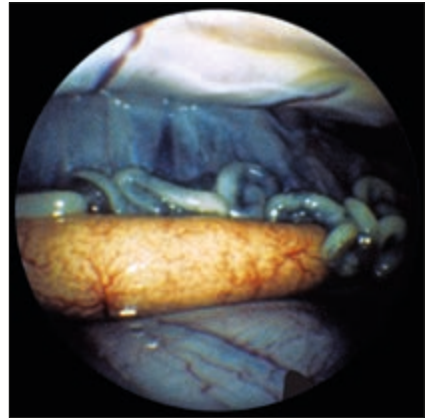
▼ Normal Endoscopic Appearance



60 Oviduct with larvae.

Toad (*Bufo alvarius*).
Within the translucent oviduct multiple black larvae with white yolk sacs are displayed.

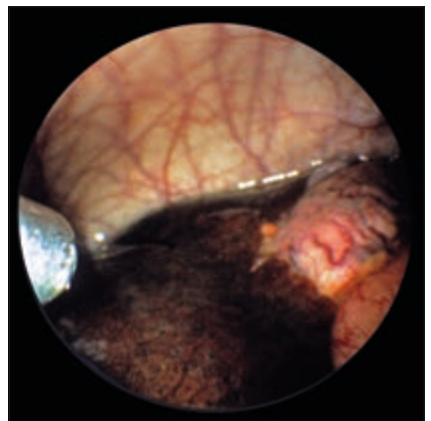▼ Normal Endoscopic Appearance



61 Testicle.

Giant Salamander (*Andrias davidianus*).
Endoscopic examination permits the identification of the sex in amphibians, the yellow, cigar shaped testicle and the white twisted vas deferens are displayed in the center.

▼ Pathological Alterations



62 Liver, Mycobacteriosis.

Toad (*Pipa pipa*).
The dark brown liver is displayed in the center and the bottom, *right*: white stomach with twisted vessels, *dorsal*: pale yellow pleuroperitoneal wall, in the center a small yellow granuloma is displayed at the rim of the liver, *left*: the endoscopic biopsy forceps, Ziehl Nielsen staining of the sample revealed a mycobacterial infection.

2.9 Literature

1. BENNETT RA: A Review of Anesthesia and Chemical Restraint In Reptiles. *J. Zoo Anim. Med.* 22(3): 282-303, 1991.
2. COOPER JE, SCHILDGER BJ: Exotic animals. In: Brearley, M.J., J.E. Cooper, M. Sullivan (ed.) *Coloured atlas of small animal endoscopy.* Wolfe Publishing, London, 93-107, 1991.
3. COPPOOLSE K: Endoscopy of the cloaca of the turtle. *Voorjaarsdagen, Proceedings, Rai-Congresscentre Amsterdam.* No. 14, 60-63, 1982.
4. DUNKER HR: Coelom-Gliederung der Wirbeltiere – Funktionelle Aspekte. *Verh. Anat. Ges.* 72, 91-112, 1978.
5. FRYE FL: Biomedical and surgical aspects of captive reptile husbandry. *Malabas, Krieger Publ.*, 4:21-437,1991.
6. GABRISCH K, ZWART P: Krankheiten der Heimtiere, K. Gabrisch und P. Zwart (ed.). *Schlutersche, Hannover*, 663-859,1998.
7. GOBEL T, JURINA K: Endoskopie des Respirationstraktes bei Reptilien. *Kleintierpraxis*, 39, 791-794, 1994.
8. HÄFELI W: Endoskopische Geschlechtsbestimmung juveniler Schildkröten. *Verh. ber. Erkr. Zootiere*, 36, 159-162, 1994.
9. KUCHLING G: Assessment of ovarian follicles and oviductal eggs by ultra-sound scanning in live Freshwater Turtles, *Chelodina oblonga.* *Herpetologica* 45(1): 89-94, 1989.
10. SCHILDGER BJ, WICKER R: Endoskopische Geschlechtsbestimmung bei *Trachydosaurus rugosus* (GRAY 1827). *Salamandra*, 23, 97-106, 1987.
11. SCHILDGER BJ, WICKER R: Endoskopie bei Reptilien und Amphibien – Indikationen, Methoden, Befunde. *Prakt. Tierarzt*, 6, 516-526, 1992.
12. SCHILDGER BJ, KRAMER M, SPORLE H, GERWING M, WICKER R: Vergleichende bildgebende Ovardiagnostik bei Echsen am Beispiel des Chuckwallas (*Sauromalus obesus*) und des Arguswarans (*Varanus panoptes*). *Salamandra*, 29 (2/3), 79-86, 1993.
13. SCHILDGER BJ ,BAUMGARTNER R, HÄFELI W, RUBEL A, ISENBÜGEL E: Narkose und Immobilisation bei Reptilien. *Tierarztl. Praxis*, 21, 361-376, 1993.
14. SCHILDGER BJ, GEYER B, KRAMER M, TENHU H, GERWING M: Vergleichende bildgebende Diagnostik der Leber bei Reptilien. *Verh.ber. Erkr. Zootiere* 36, 151-158, 1994.
15. SCHILDGER BJ: Endoskopische Untersuchungen des Urogenitaltraktes bei Reptilien. *Verh. ber. Erkr. Zootiere, Dresden*, 305-308, 1995.
16. SCHILDGER BJ, KUCHLING G: Endoscopic diagnosis and therapy of *Austrampholina* sp. infection in the narrow-breasted snake-necked turtle. *Herpethopathologica*, 67-68, 1995.
17. SCHILDGER BJ: Zur Technik der Gastroskopie bei Schildkröten. *Verh. ber. Erkr. Zootiere*, 38, 73-75, 1997.
18. SCHILDGER BJ, HÄFELI W, KUCHLING G, TAYLOR M, TENHU H, WICKER R: Endoscopic examination of the pleuroperitoneal cavity in reptiles. *Sem. Avian Exotic Pet Med.*, 1998, in press.
19. WOOD CR, WOOD FE, CHRICHTLEY KH, WILDT DE, BUSH M: Laparoscopy of the green turtle, *Chelonia mydas*. *Brit. J. Herpetol.* 6, 323-327, 1983.

ENDOSCOPY IN FISH



**Michael J. MURRAY, DVM,
Monterey Bay Aquarium, Monterey, U.S.A.**

Endoscopy in Fish

Michael J. MURRAY, DVM
Monterey Bay Aquarium
886 Cannery Row
Monterey, CA 93940
Phone: +1-4086484800
Fax: +1-4086484810

3.0 Endoscopy in Fish

3.1 Introduction

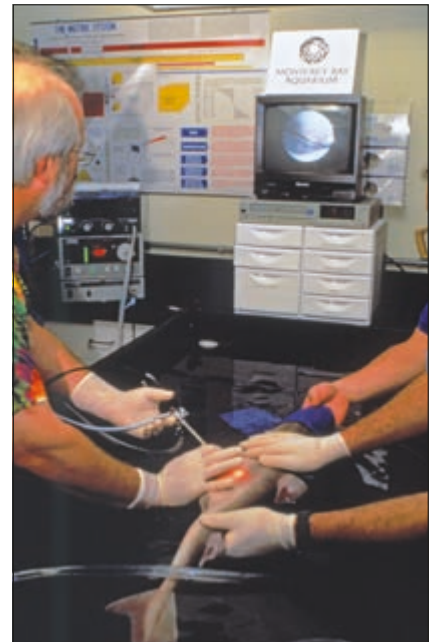There has been a veritable explosion in the popularity of the public aquarium throughout the world over the past decade. Coupled with the newer artificial seawater and enhanced life support systems, newer aquaria are no longer limited to marine coastal areas. This increased public interest in the aquatic habitat and its inhabitants has been accompanied by an enhanced awareness of the impact that man has upon the fresh and marine waters of the planet. This change in attitude has carried into the captive management of the fish. No longer is the treatment of choice for the fish merely replacement therapy. Additionally, aquaculture has become increasingly important as a source for food fish for human consumption.

These changes have placed an increased emphasis on the veterinarian's ability to diagnose and subsequently treat diseases of the fish. At the same time, the availability of high quality rigid endoscopic equipment has increased. While rigid endoscopy has typically been applied to avian and equine species in the veterinary field, modifications of human-use equipment are easily utilized in the piscine patient. These fine diameter, rigid endoscopes permit the veterinarian visualization of a variety of coelomic structures with minimal invasiveness. A sheath system may be added, allowing the collection of a variety of targeted biopsy specimens for evaluation. Rigid endoscopy with its inherent focal, directed illumination with magnification allows the clinician the opportunity to directly visualize coelomic structures, as well as collect diagnostic samples for an etiopathogenic diagnosis, even in species often deemed problematic, such as fish.

3.2 Anatomy

In no other vertebrate group is there as much variation in anatomy, as one encounters in the fishes. While one may tend to create a „generic“ fish, such as the trout, a fusiform teleost, dramatic diversity exists. External form varies from the fusiform shape, to dorsoventrally or laterally compressed, and even eel-like body configurations. In each, arrangement of the coelomic viscera has been modified. It is, therefore, incumbent upon the clinician to be aware of the anatomy of the fish in question. Application of even the minimally invasive endoscopic procedures require this basis before use.

Despite this idiosyncrasy, piscine laparoscopy provides excellent visualization of a variety of viscera. While in most cases, the liver will be the most readily visualized organ, gonad, spleen, gastro-intestinal tract, peritoneal fat, and unique organs such as the rectal gland of sharks and the spiral valve of elasmobranchs is often accessible. As the telescope is advanced cranially, the pericardial space is visualized. In most species, the heart may be observed to beat within this cavity. More dorsally located structures, such as the swim bladder or kidneys require rotation of the fish to a more lateral or ventral position for adequate examination.



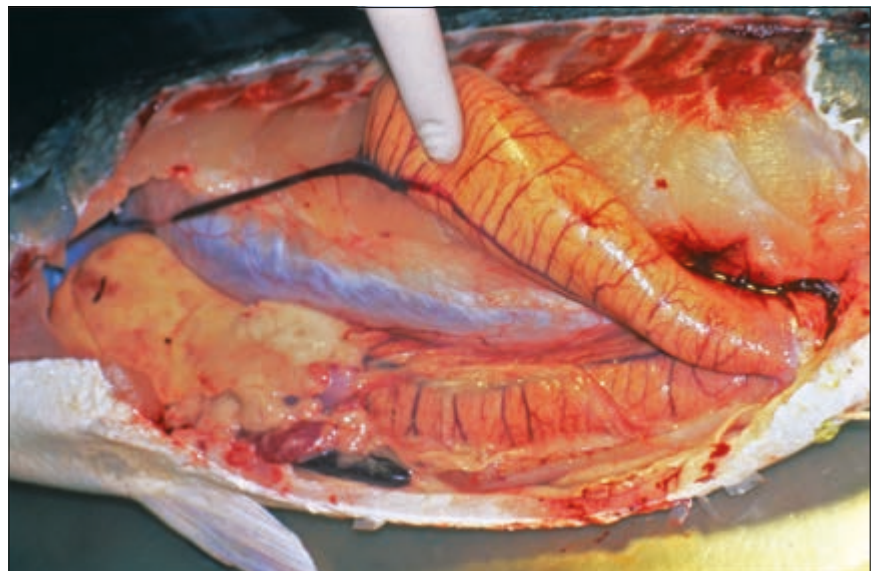
1 Endoscopic examination of the spiny dogfish (*Squalus acanthias*). (Photo courtesy of Randy Wilder, Monterey Bay Aquarium).

Of particular note in the discussion of anatomy is the effect that increased amounts of abdominal fat have upon thorough endoscopic examination. Fat not only obscures normal anatomy, but also tends to foul the distal tip of the telescope interfering with visual resolution. This increased fat is most likely secondary to the relatively sedentary life style of many of the fish maintained in public aquaria. Additional reduction in endoscopic working space is noted in the gravid female fish. In these cases, exceptional care must be taken to avoid damaging either the ovary or the ventrally displaced colon.

3.3 Indications

The use of endoscopy in fish is not a novel idea. While limited, there are some reports of the use of the rigid endoscope as a diagnostic aid in piscine species. Most applications suggest the laparoscope for evaluation of reproductive status in fish. In an early report, a single puncture technique using a 1.7 mm rigid telescope with a 2.0 mm trocar sleeve is described. (MOCCIA, et al 1984) In this report, insufflation is accomplished through the injection port associated with the trocar sleeve. Other researchers have described the use of the genital pore as an access point, when the indication for laparoscopy is the determination of reproductive status (ORTENBURGER, et al 1996). A very limited description of the use of laparoscopy in the shark has also been published (STOSKOPF 1993).

In general, however, the indications for endoscopy in fishes mirror those described for other species. Endoscopy may be employed for sex identification in monomorphic or juvenile species; management of reproduction; examination of coelomic viscera and collection of diagnostic specimens; removal of foreign bodies; and performance of minimally invasive surgical techniques. The endoscope may also be used to examine regions of „external anatomy“ which cannot be accessed otherwise, such as the area around the gills and oral cavity.



2 The coelomic cavity of the “typical fusiform teleost” fish (striped bass, *Morone saxatilis*) leaves little working room for the endoscopist. The ovary is the paired, granular structure, one of which is being reflected. Also visible is the pale yellow liver, silver swim bladder, and the dark red spleen.

3.4 Anesthesia


Fish physiologists continue to argue whether or not fish perceive pain. All agree that the fish is capable of sensing environmental cues, but it is not clear whether noxious stimuli are recognized as such within the central nervous system. That being said, however, veterinarians should err on their patients' behalf and administer appropriate forms of anesthesia to preclude pain sensation, assuming there is such a thing in the fish. Regardless of their ability to sense pain, fish will definitely respond, often violently, to the minimally invasive techniques associated with laparoscopy. The force of the struggling piscine patient is best not unleashed against the relatively delicate nature of the rigid endoscope and associated equipment.

Tricaine methanesulfonate (MS-222) is the anesthetic of choice for laparoscopy. This compound is a derivative of benzocaine, to which an additional sulfonate radical has been added. This addition makes tricaine more water soluble, but in solution is acidic. Advantages of this anesthetic compound include its availability, relative inexpense, rapid onset and rapid recovery. A further advantage is that tricaine is a compound that has been approved for use in food fish. This is not only important in aquaculture, but also in the public aquarium industry when the potential for release of anesthetized fishes which may enter the human food market is to be considered. The withdrawal time in the USA is 21 days. The primary disadvantage of tricaine is its inherent acidity in aqueous solution. Sea water tends to have adequate buffering capacity to ameliorate the effects, however, fresh water anesthetic baths must be buffered to preclude substantial irritant effects upon the gills. Tricaine has also been noted to act as a hypoxic agent. This may occur secondary to depression of the medullary respiratory center, bradycardia, and changes in blood flow through the gill lamellae. There may be post anesthetic changes in renal function, causing electrolyte loss, for up to 7 days after recovery.

Fish are anesthetized in a bath containing 75–100 ppm (mg/L) of tricaine methanesulfonate into which an air stone is placed. Freshwater species are immersed in a similar concentration to which sodium bicarbonate is added to buffer the water to a pH of 7.0–8.0 (typically 1 part MS-222 : 2 parts NaHCO_3). As the fish enters a state of deep narcosis, it can be removed from the induction bath. This stage of anesthesia is identified by a loss of response to postural changes, a slightly decreased respiratory rate, loss of equilibrium, decreased muscle tone, and a slight to moderate response to painful stimuli.

The fish can then be placed in dorsal recumbency within a „water table“ and foam rack with padded, non-abrasive vertical sides. Anesthesia is then maintained with a concentration of tricaine between 60–75 ppm administered with a recirculating anesthetic machine (LEWBART 1995). This device consists of two vessels of water, one with tricaine, one without. An immersible pump is attached to a flexible tube placed in the fish’s mouth directing flow over the gills. A T-valve located at the outflow of the water table permits the anesthetist to direct outflow water to either reservoir. The goal of the anesthetic is to maintain the patient within a light anesthetic plane, with a total loss of muscle tone; slow, but regular respiratory rate; and response only to deep pressure. As the fish enters too deep a plane of anesthetic; loss of any reactivity, very slow or absent respiratory rate, the pump is shifted to move non-anesthetic laden water over the gills. In this way, the appropriate anesthetic level can be maintained. Following laparoscopy, the fish is moved into a vessel of clean water with an elevated dissolved oxygen content. Assisted swimming in order to continue the forward motion of the fish may be utilized until the fish becomes ambulatory.

Other anesthetic protocols may have application for laparoscopy. Certain species, such as the Scombridae, tunas and mackerel, may not adapt well to the confinement associated with tricaine induction. Parenteral agents, such as ketamine, may be indicated for anesthetic induction, followed by „inhalant“ agents as indicated. Tonic immobility, induced by hyperoxygenation and postural changes is probably inadequate for the degree of stimulation provided by an endoscopic examination.



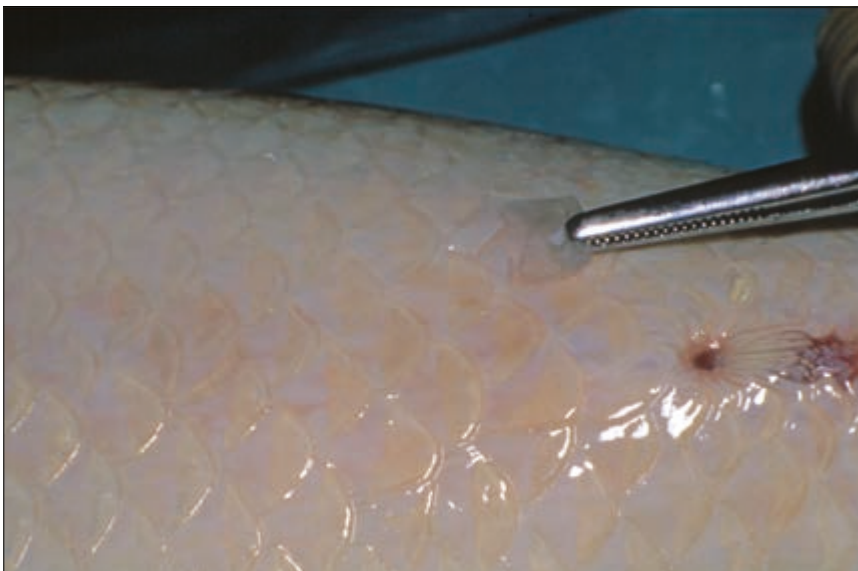3 The anesthetic water table in which anesthetic laden water is pumped from the reservoir underneath to the gills of the fish. The red-handled valve can divert water back into the reservoir, or to discharge. At that point, non-anesthetic laden water can be pumped over the fish’s gills to lighten the anesthetic plane.

3.5 Endoscopic Technique

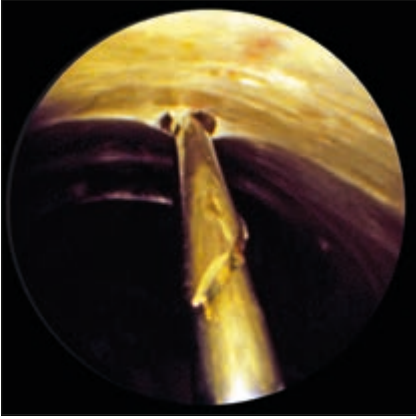
As with any other species, laparoscopy should be performed utilizing aseptic technique. With the fish in dorsal recumbency, insertion points may be gently prepared utilizing a povidone-iodine solution. In scaled fish, individual scales may be removed with forceps to facilitate entry. A sterile, clear drape may be utilized to isolate the surgical field. As towel clamps are excessively traumatic, the drape may be „adhered“ to the fish by pressing it into a thin bead of gel placed around the incision. The barrier must be substantial enough to keep water out of the incision, as the area should be periodically moistened to keep the fish’s skin from drying out.

Attempts to visualize viscera without distention of the body cavity may be problematic. The tightly packed coelomic cavity leaves little room for instrument manipulation without iatrogenic trauma. Attempts to distend the coelom with saline infused through the injection port of the trocar sleeve may increase the working space, however, visualization may be hampered as a result of the suspension of fat droplets within the instilled saline.

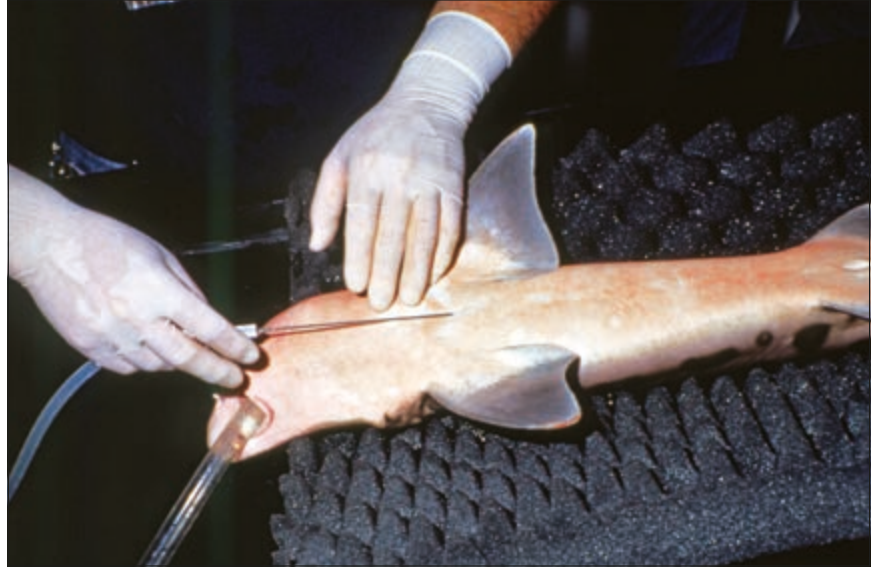Traditional insufflation with carbon dioxide gas is the preferred technique. Carbon dioxide is relatively inert, non-combustible, and appears to be well tolerated by the patient. In human and veterinary laparoscopy, carbon dioxide is the insufflation gas of choice. In the piscine patient, as much CO₂ as possible should be removed from the coelom at the end of the laparoscopic procedure. Residual gas appears to have no significant effect on the fish’s ability to maintain its position and posture within the water column. Fish with or without swim bladders seem relatively unaffected post-operatively.



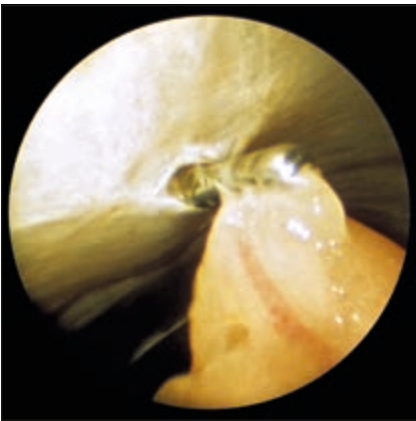
4 In scaled fish, individual scales should be plucked to facilitate entry of both the Veress needle and the endoscopic equipment.



5 A properly placed Veress needle without trauma to viscera, facilitating adequate insufflation for endoscopic examination.



6 The Veress needle is inserted just caudal to the pectoral girdle. A shallow angle of entry decreases the chances of iatrogenic trauma to coelomic structures.



7 Inadvertent entrapment of coelomic fat by the Veress needle. A shallower angle of entry and a slower introduction of the needle aid in prevention of this iatrogenic problem.

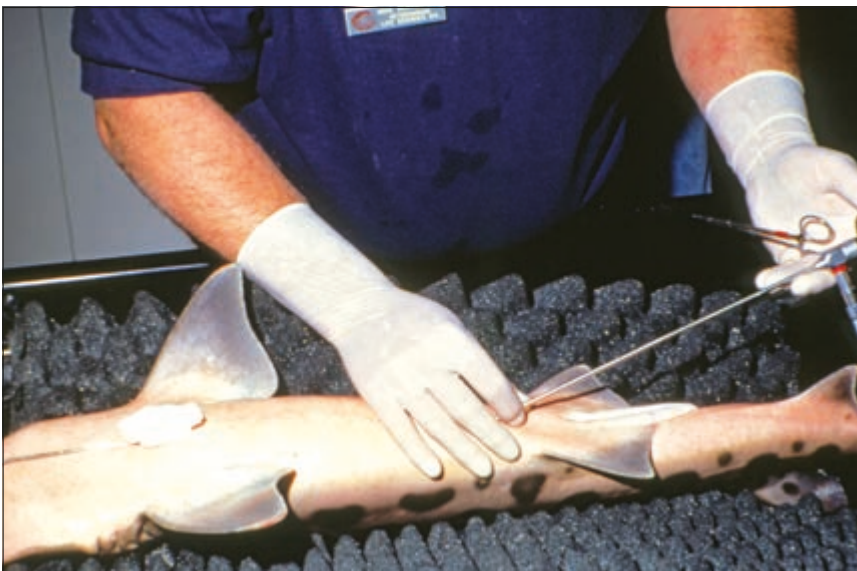

8 After surgical preparation, barrier drape placement, the coelom is insufflated. The hemostatic forceps have bluntly dissected through the body wall prior to introduction of the endoscope.

It was found that use of a Veress needle provides the best insufflation. The needle is inserted on the ventral midline just caudal to the pectoral girdle. Following appropriate skin preparation, a 1mm stab incision is made just through the skin with a #11 scalpel blade. The Veress needle is then gently advanced at an angle just off parallel to the skin to enter the coelomic cavity. This increased tunneling, contrary to the perpendicular approach employed in mammalian laparoscopy, facilitates a more water tight seal after the needle has been removed. Additionally, the body wall can not be elevated in the mammalian fashion, therefore, a more shallow angle decreases the chances of iatrogenic trauma.

Once the Veress needle is in place, CO₂ insufflation can occur. In most cases, a peak insufflation pressure of 10 mm Hg is adequate. In some species, such as the bat ray, *Myliobatis californica*, pressures of 10 mm Hg may cause prolapse through the rectum. Lower pressures combined with occlusion of the excretory orifice provide adequate insufflation.

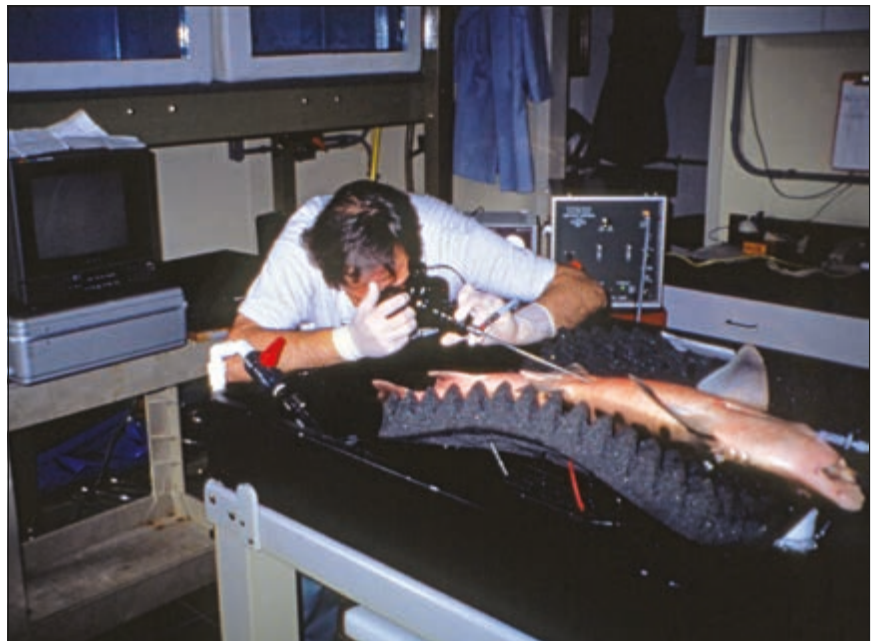Once the coelomic cavity has been adequately distended, the telescope may be inserted. The exact point of entry is determined by the nature of the laparoscopic procedure. In most cases, the author has found the best approach to be located on or just lateral to the ventral midline just cranial to the vent or genital pore. In some species, such as many teleosts or potentially gravid females, entry lateral to the midline is be advisable. This reduces the potential for inadvertent perforation of the gastro-intestinal or reproductive tracts.



9 The tip of the endoscope is introduced very slowly to permit re-inflation of the coelom by the insufflator.

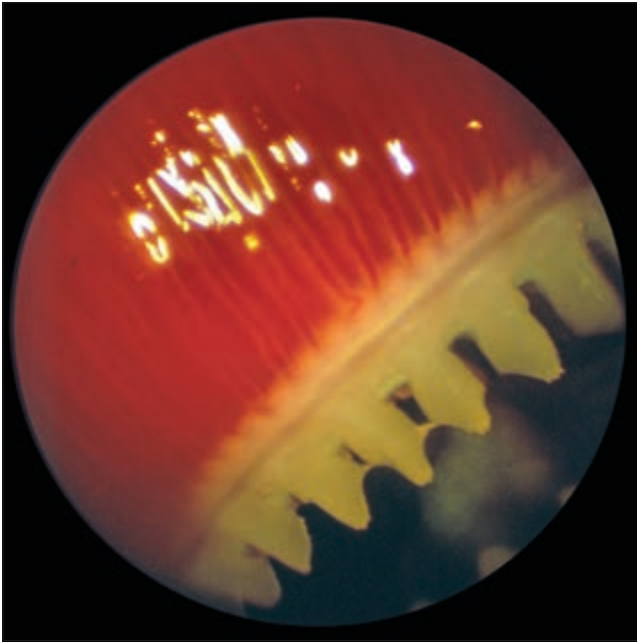
Once the entry site is prepared, a 1–2 mm stab incision is made through the skin. A pair of fine mosquito forceps may then be used to bluntly dissect between muscle fibers to enter the coelomic cavity. Entry into this space is confirmed by the audible sound made by the escape of insufflation gas. The forceps are then removed and the telescope inserted in their place. The tip of the telescope should initially be placed just within the coelomic cavity. This will allow maximal distention of the cavity, as some of the gas tends to escape during entry. Once the telescope is in place the remainder of the laparoscopic examination may proceed as in any other species, including the collection of diagnostic specimens utilizing the sheath system and its integral instrument channel. After completion of the laparoscopic procedure, as much CO₂ gas as possible should be milked out of the body cavity. The skin defect may then be closed with a monofilament, polyglactin suture material. The Veress needle defect tends to be self-sealing, but may be sutured if indicated.

To facilitate visualization, the patient may be rotated into lateral or even ventrolateral recumbency. In certain species, the swim bladder occupies a relatively large proportion of the coelomic cavity. In these cases, the swim bladder may be partially deflated utilizing the Teflon guarded needle associated with the sheath system. These fish tend to return to a normal position within the water column within a very short period.

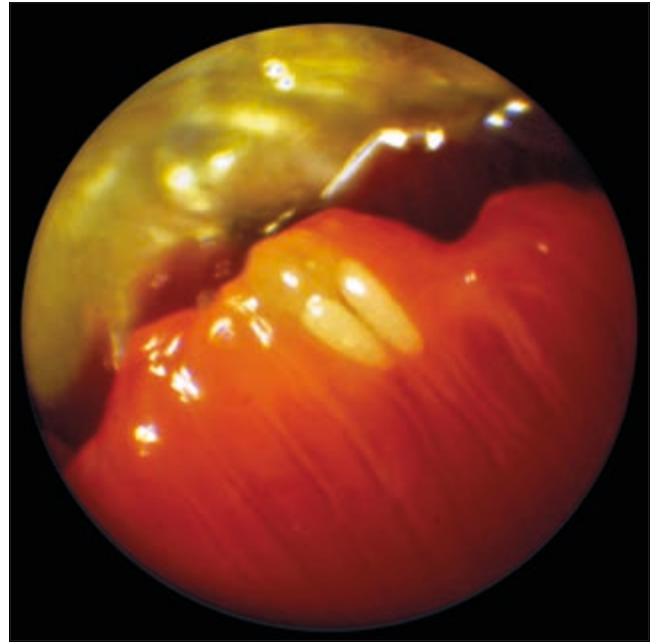


10 While unique, the fish's coelomic cavity will permit the entire range of endoscopic procedures routinely utilized in birds and reptiles. Note the padding underneath the fish. Notches have been cut out to accommodate the dorsal fins of this leopard shark (*Triakis semifasciata*).

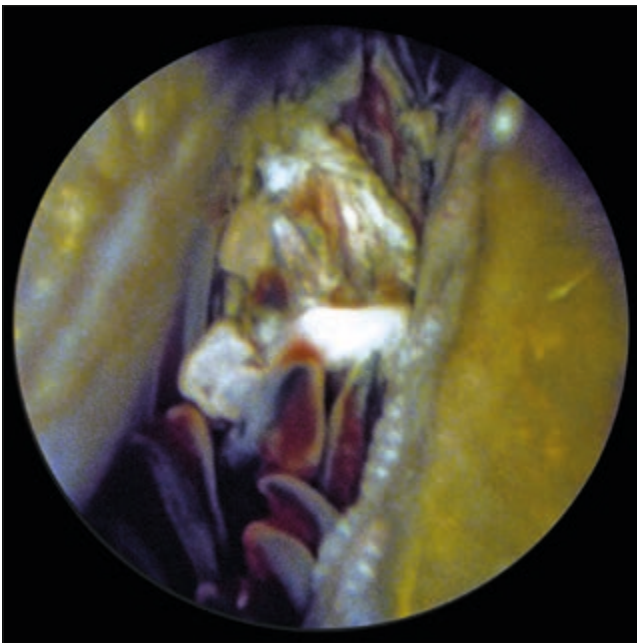
3.6 Samples of Endoscopic Features of Fish



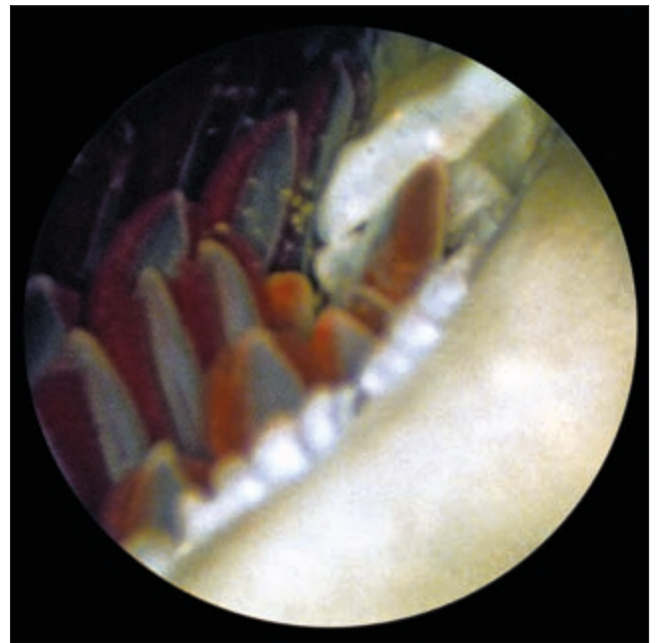
11 Attachment of the gill filament (primary lamellae) to the gill arch of the gopher rockfish (*Sebastes carnatus*). The white colored gill raker is located on the cranial aspect of the gill arch; the lamellae on the caudal edge.



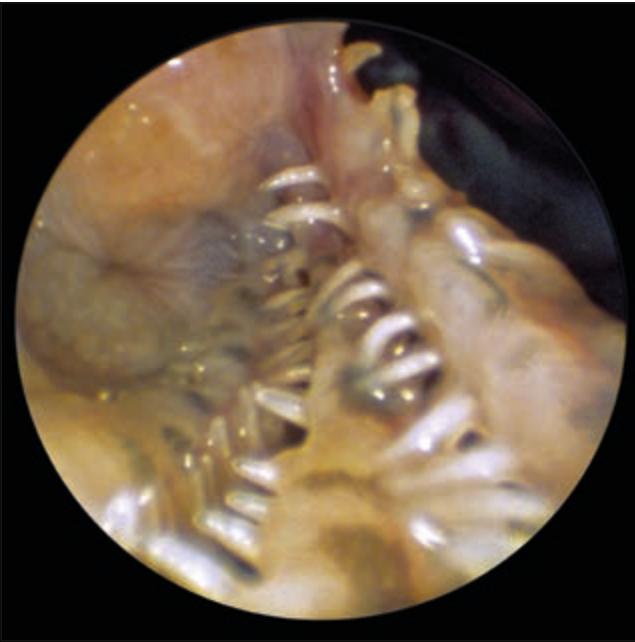12 Parasitic copepod, *Naobranchia occidentalis*, attached to the distal aspect of the gill filament of the same gopher rockfish presented in figure 12. Parasites such as this commonly cause significant gill pathology, such as the shortening and blunting noted here.



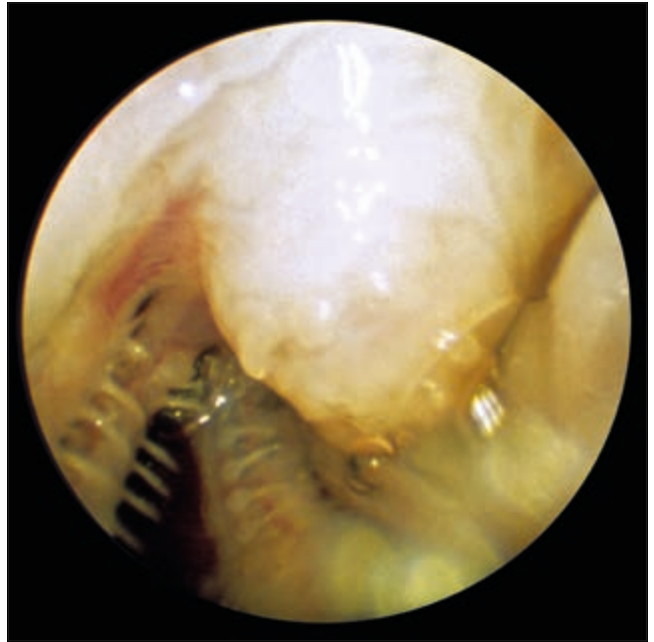13 Heavy infestation with the monogenic trematode, *Nitzschia quadritestes*, in the white sturgeon, *Acipenser transmontanus*. While the flukes seen here are quite obvious protruding from the operculum, they may be cryptically concealed in the depths of the gill chamber, in which endoscopy is a valuable diagnostic aid.



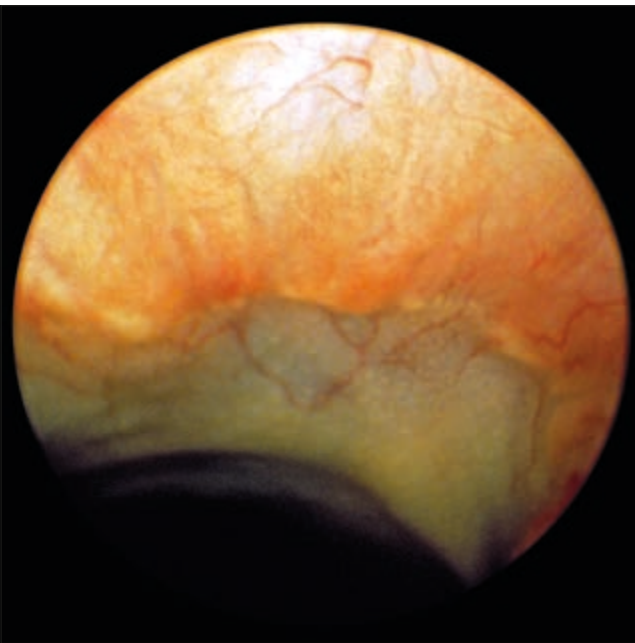
14 A second view of the previous case. Note the blunted appearance of the gill filament and the development of pigmentary changes secondary to the chronic irritation caused by the parasites.



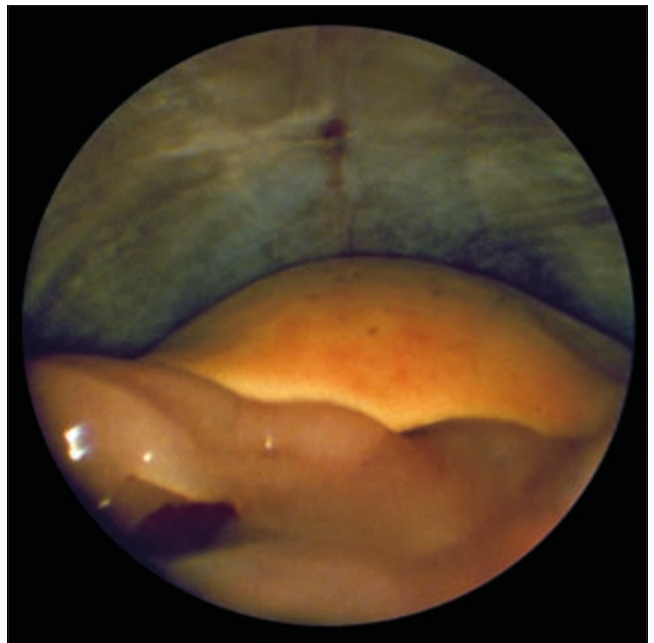
15 View of the gill rakers from the oral cavity of the wolf-eel (*Anarrhichthys ocellatus*). These structures serve to preclude the entry of food material into the gas exchange area of the gills. Their shape is often used as a taxonomic aid and may suggest the dietary habits of the fish, in this case hard shelled invertebrates and fishes. The roseate shaped opening of the esophagus is also visible.



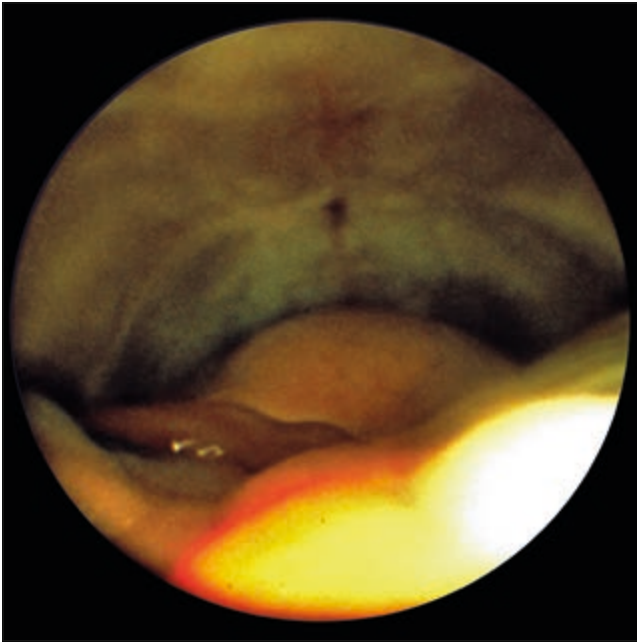
16 The caudal aspect of the oral cavity of the wolf-eel has this protrusion upon which the translucent pharyngeal teeth are located. They tend to aid in holding prey items in the appropriate orientation for swallowing.



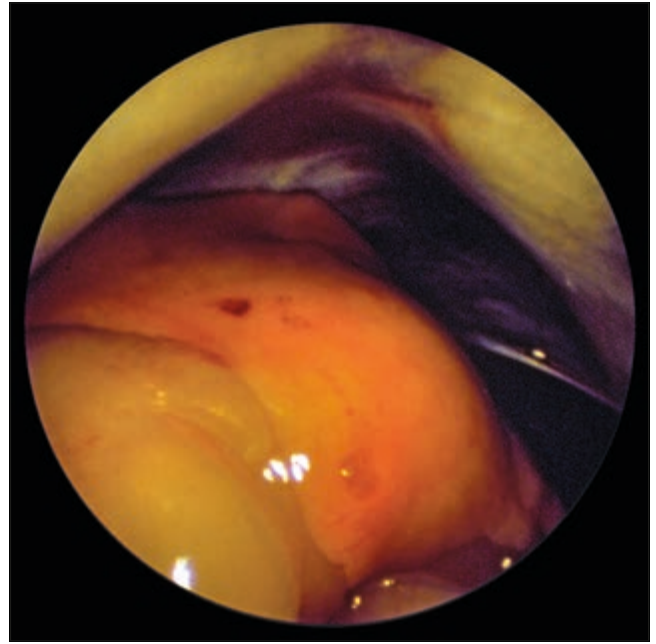
17 In the wolf-eel there is a dramatic demarcation between the relatively aglandular esophagus and the glandular stomach. The openings of the gastric glands can be visualized as the miliary white foci within the stomach lumen depicted here.



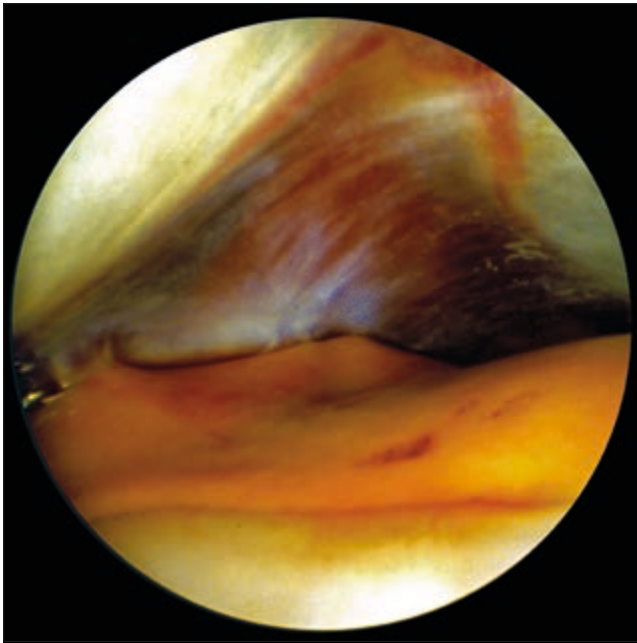
18 A view of the distended coelomic cavity of the copper rockfish (*Sebastes caurinus*) in dorsal recumbency. The liver is the yellowish structure in the background. The off-white colored fat is another predominant feature with a small portion of the spleen visible as the deep red colored organ within the fatty tissue.



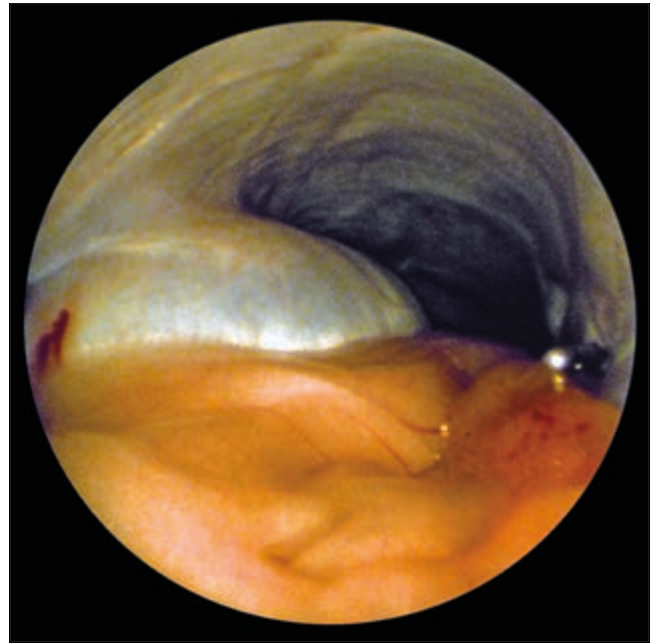19 Another view of the coelom of the same copper rockfish. In addition to the liver and fat, the yellow-orange testes is also noted in the foreground.



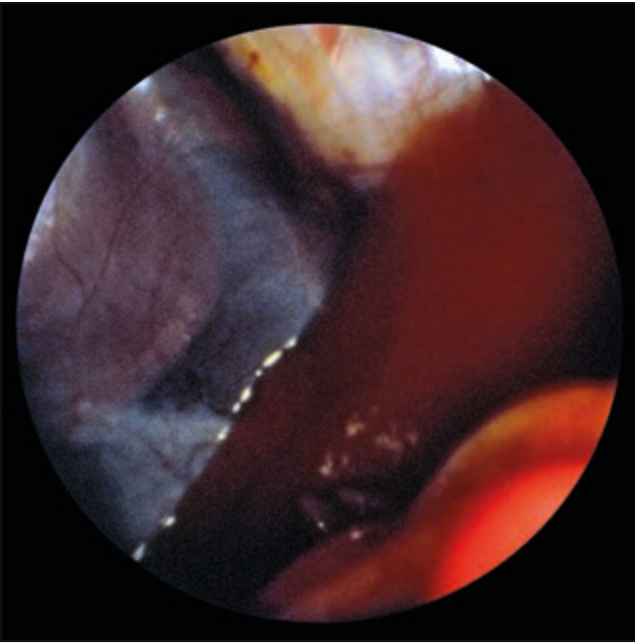20 The liver of this gopher rockfish (*S. carnatus*) contains multiple parasitic cysts. The exact etiopathogenesis of this type of gross change is difficult to determine without biopsy.



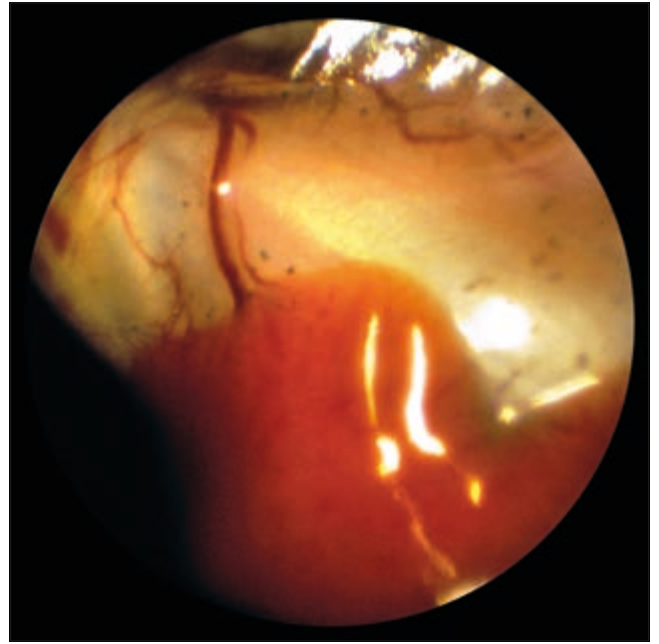
21 As the telescope is advanced cranially, the heart can be visualized within the pericardial space. Looking into this region, one can easily identify the heart's ventricle with the apex directed upwards (the fish is in dorsal recumbency).



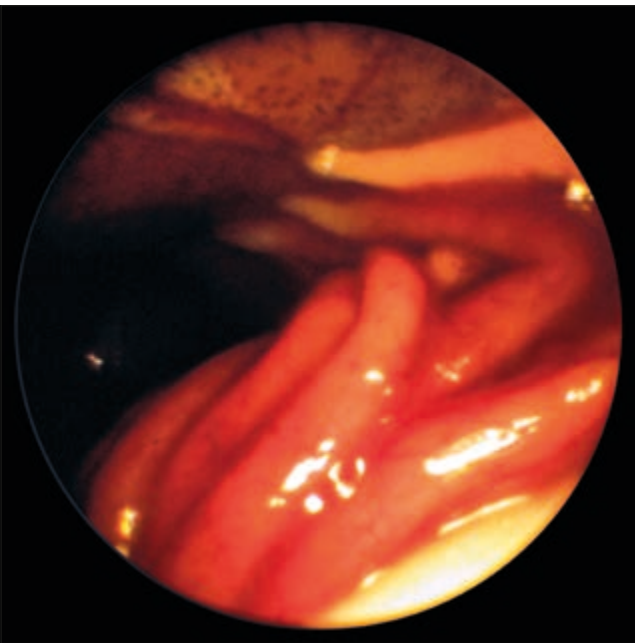
22 Gopher rockfish (*S. carnatus*) in lateral recumbency. The ventral body wall is identified by the presence of the metallic tip of the Veress needle. The reflective, silver swim bladder is somewhat over distended, as this fish was captured in deeper waters. The ovary is partially exposed within the fat adjacent to the ventral body wall.



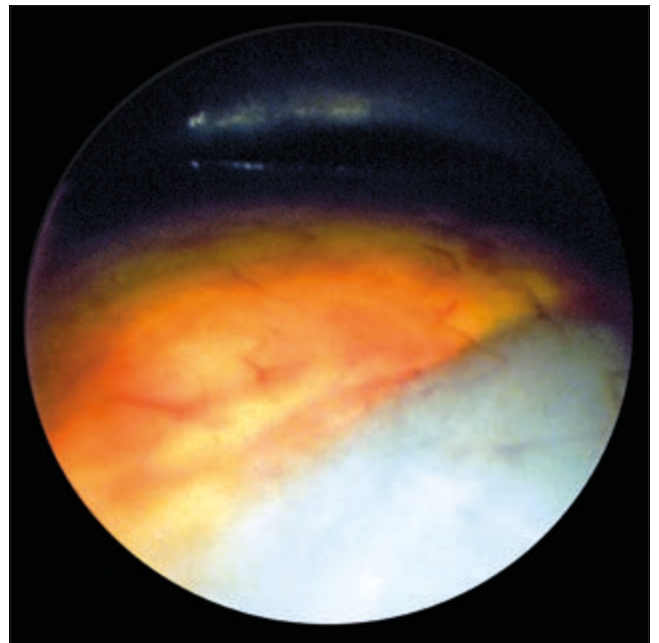
23 Parasitic changes are visible as irregular white plaques on the ventral aspect of the liver in this Pacific mackerel (*Scomber japonicus*). The heart is visible within the pericardial space, and the distal aspect of the stomach is the red-pink structure in the foreground. Several of the pyloric caecae are identified just under the hepatic lesions.



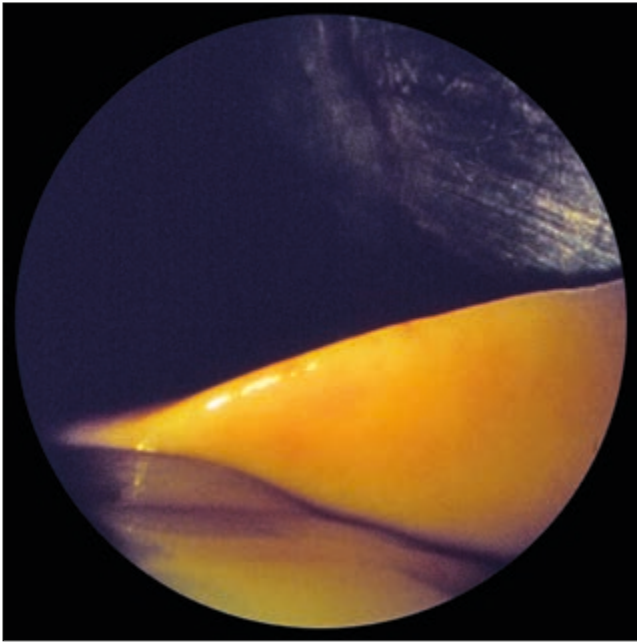
24 A portion of the liver is observed overlying the ventral aspect of the swim bladder of the Pacific mackerel. The dark pigmented regions in the sub-peritoneal area are caused by accumulations of melano-macrophages.



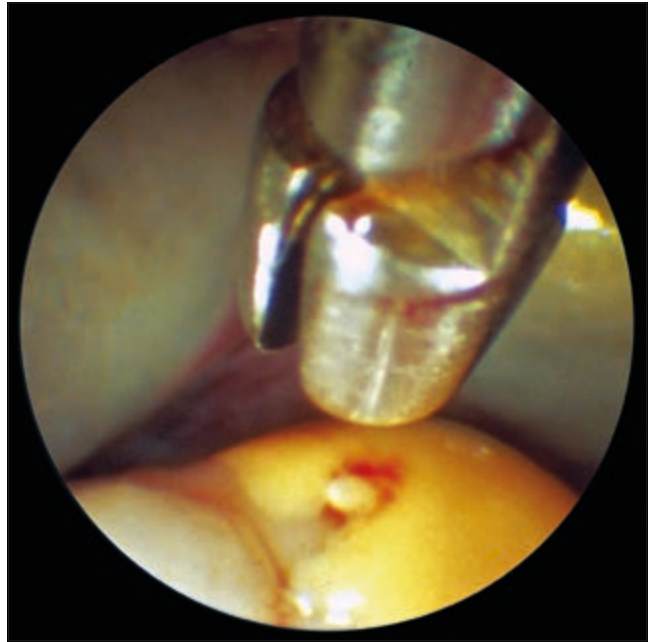
25 Pyloric caecae in the Pacific mackerel (*S. japonicus*). Similar structures are found in the region of the pylorus of salmonids, such as trout and salmon.



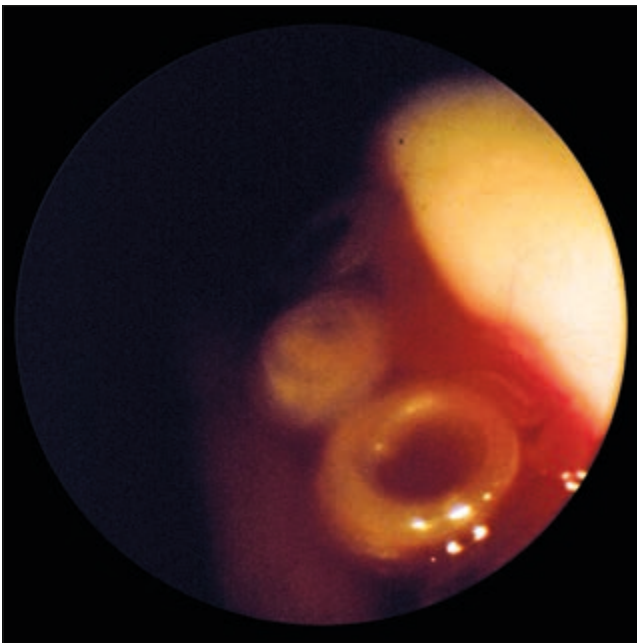
26 The pale liver of the bat ray (*Myliobatis californica*) overlying the stomach. Accumulations of large amounts of fat within the liver of fish, particularly elasmobranchs, is common, as it is used as an energy depot. The increased vascular pattern on the surface of the organ is commonly observed, and appears to be within normal limits.



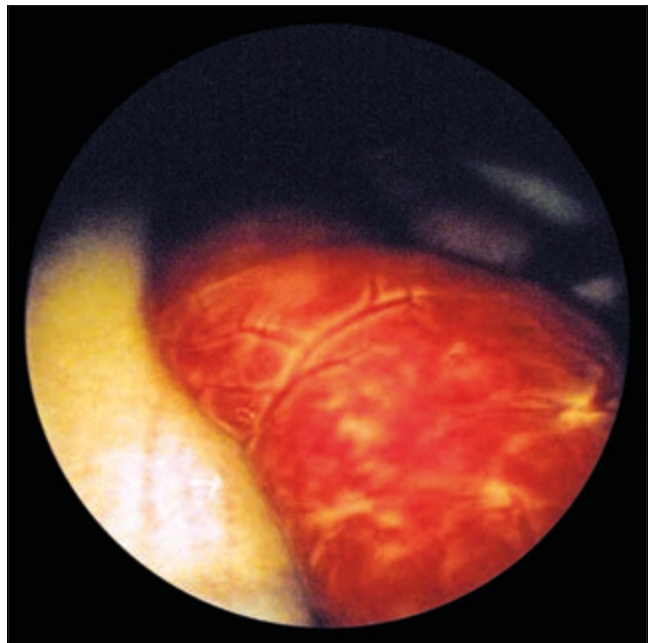
27 The caudal margin of the liver is easily elevated and quite accessible for biopsy. Again, the degree of hepatic lipidosis is not unusual in this species, the leopard shark, *Triakis semifasciata*.



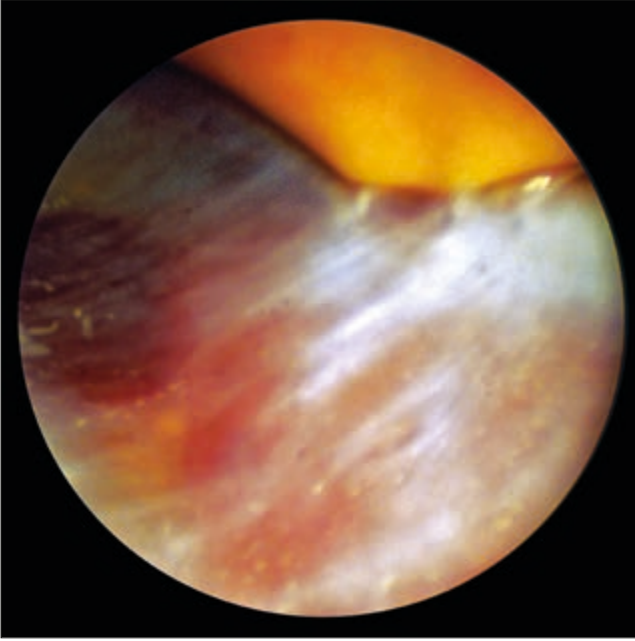
28 A post liver biopsy photograph in the gopher rockfish (*S. carnatus*). The degree of hemorrhage associated with liver biopsy is typically quite limited.



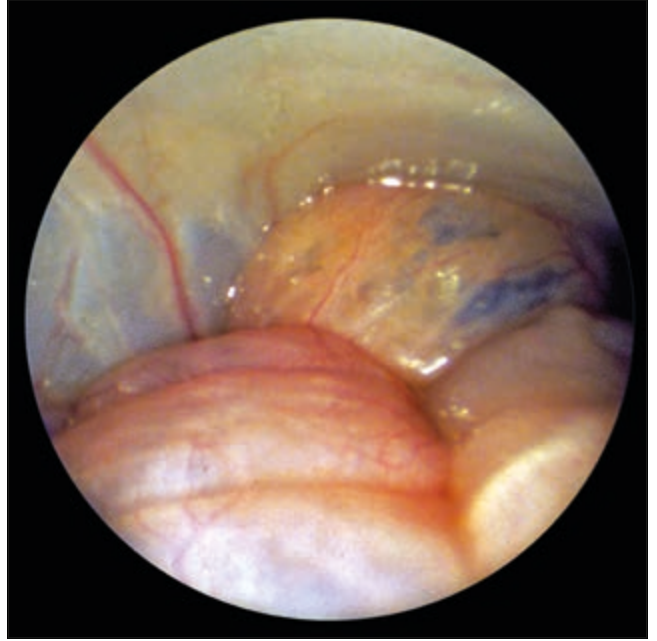
29 Subserosal nematode parasitism in the Pacific mackerel (*S. japonicus*). Nematodes are commonly found in this group of fish, the Scombridae.



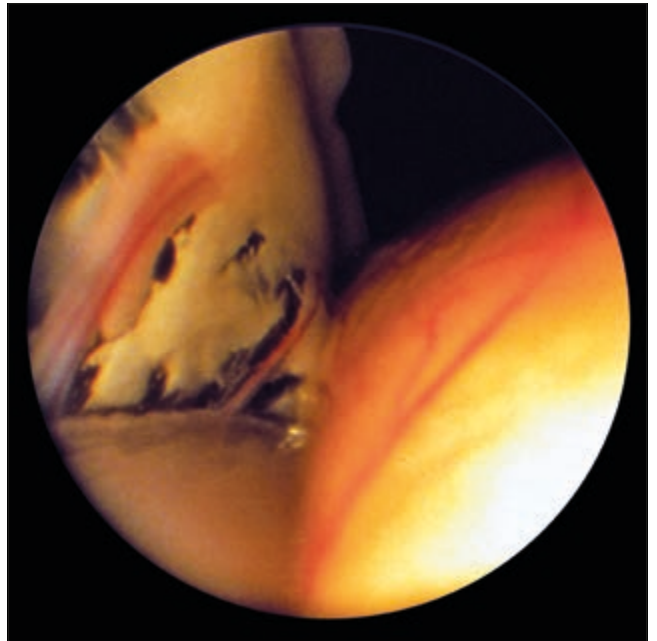
30 The large red spleen of the leopard shark (*Triakis semifasciata*) is easily identified just ventral to the stomach. This organ has both hematopoietic and lymphomyeloid tissue.



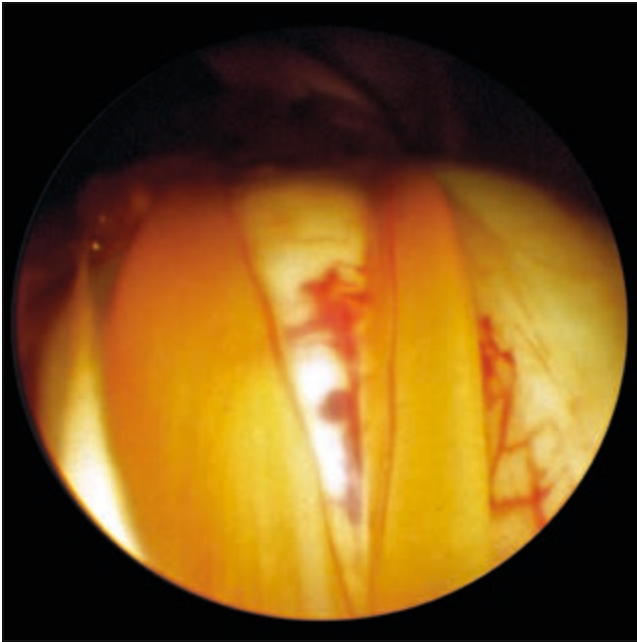
31 The kidney, located retroperitoneally may be difficult to identify and access in many fish. With the fish rotated into ventro-lateral recumbency, viscera may be moved away from the dorsal body wall, thereby exposing the kidney. In certain individuals, partial deflation of the swim bladder is also helpful. This photo was taken in the gopher rockfish (*S. carnatus*).



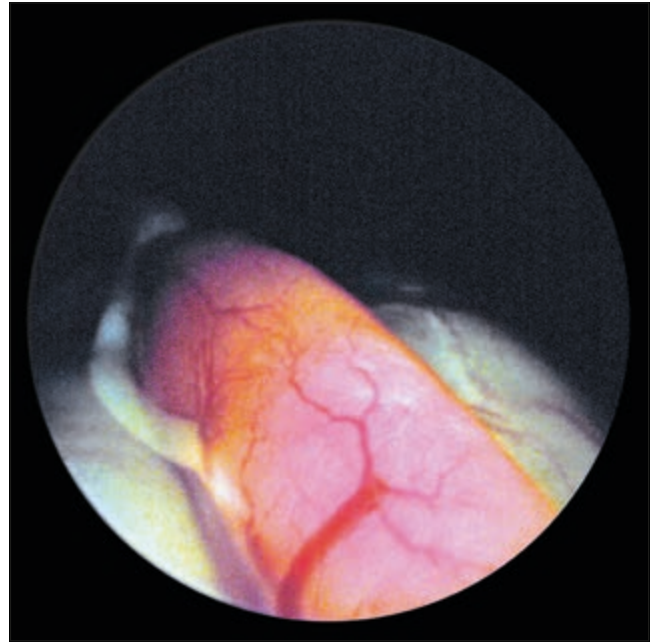
32 Dilated intestinal loops in the wolf-eel (*Anarrhichthys ocellatus*). In this case, the distension was iatrogenically induced by insufflation of the stomach for endoscopic examination.



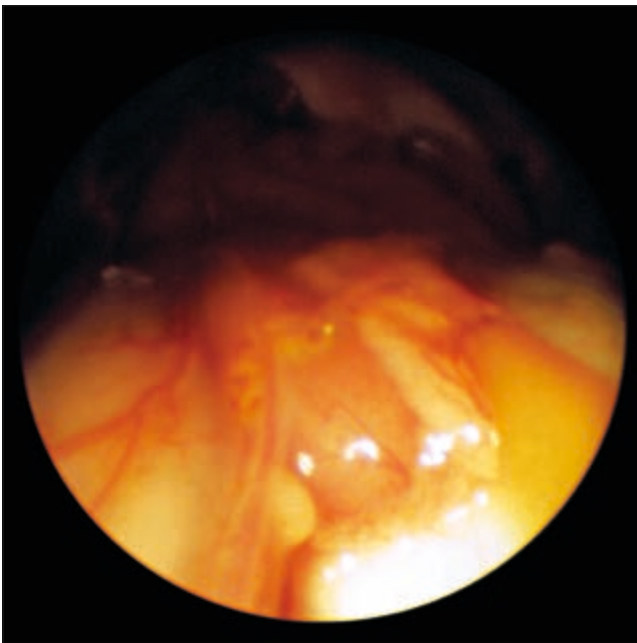33 The ventral mesentery of the gopher rockfish (*S. carnatus*) contains minimal vasculature and multiple fat bodies. The ovary is the yellowish structure with overlying vessels. The colon is seen as a white, tubular structure associated with the mesentery.



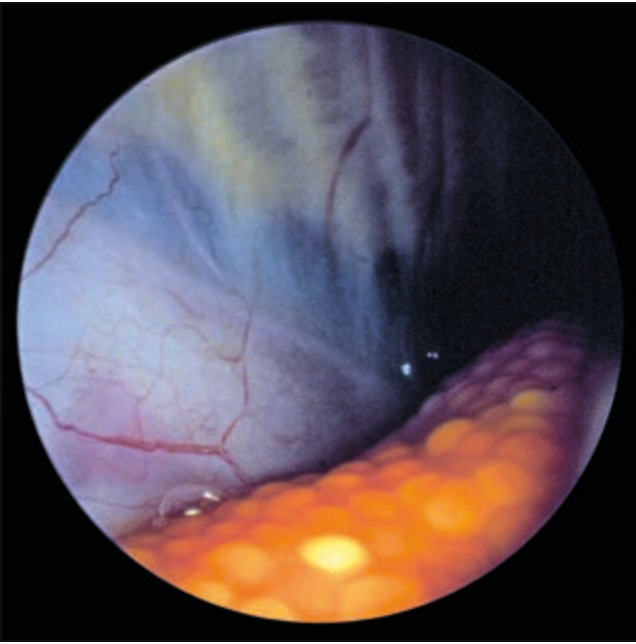
34 Paired, yellow-orange testes in the leopard shark (*T. semifasciata*). The testes are found on the ventral floor of the coelom just underneath the gastro-intestinal tract; here seen as the off-white organs with the vascular supply. The liver is barely visible in the background (cranially).



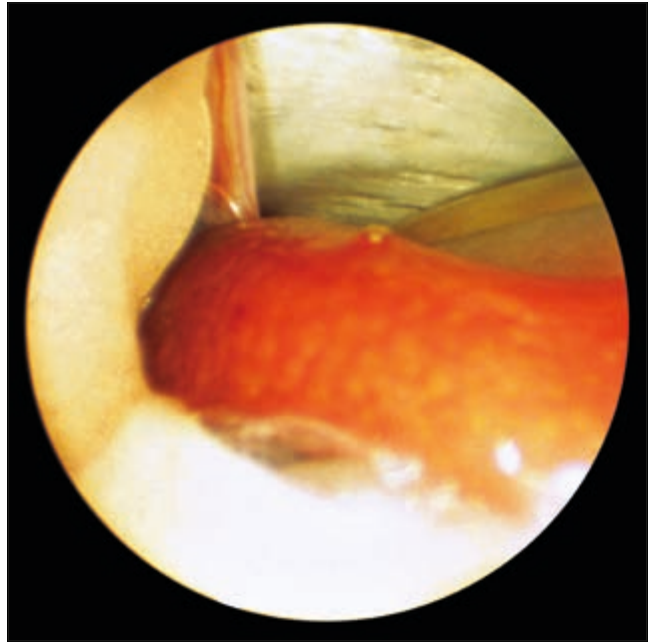
35 With the testicle reflected slightly laterally, its arborizing vascular supply is easily visualized. A cestode is also observable within the coelomic cavity.



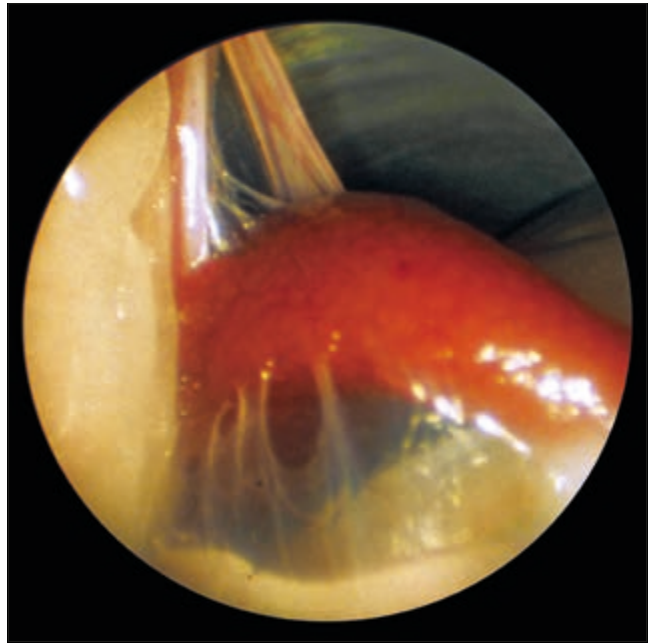36 The testicles of the gopher rockfish (*S. carnatus*) are seen here closely associated with the intestine. Looking cranially, one can also identify the liver.



37 Maturing ova within the ovary of the king salmon (*Onchorhynchus tshawytscha*) are readily identified. The medial aspect of the ribs can also be visualized in this photograph.



38 While not quite so obvious, one can distinguish the ovary of this gopher rockfish (*S. carnatus*) by its somewhat granular appearance.



39 The dorsal and ventral suspensory ligaments of the ovary are easily distinguished. The shape of the ovary becomes more tapered at it nears the genital pore. In this case, the fish is in ventral recumbency, with the more vascular suspensory ligament extending dorsally.

3.7 Literature

1. TAYLOR M: Diagnostic application of a new endoscopic system for birds. *Proc Eur Conf Avian Med Surg*, 1993; 127-131.
2. MOCCIA RD, WILKIE EJ, MUNKITTRICK KR, THOMPSON WD: The use of fine needle fibre endoscopy in fish for in vivo examination of visceral organs, with special reference to ovarian evaluation. *Aquaculture* 1984; 40: 255-259.
3. ORTENBURGER AL, JANSEN ME, WHYTE SK: Nonsurgical videolaparoscopy for determination of reproductive status of the Arctic charr. *Can Vet J* 1996; 37: 96-100.
4. STOSKOPF MK: Surgery. In: Stoskopf MK (ed). *Fish Medicine*. Philadelphia, PA: WB Saunders Co, 1993: 91-97.
5. BROWN LA: Anesthesia and restraint. In: Stoskopf MK (ed). *Fish Medicine*. Philadelphia, PA: WB Saunders Co, 1993: 79-90.
6. LEWBART GA, STONE EA, LOVE NE: Pneumocystectomy in a Midas cichlid. *JAVMA* 1995; 207(3): 319-321.
7. LACY A, BLANCH S, VISA J: Alternative gases in laparoscopic surgery. In: Rosenthal RJ, Friedman RL, Phillips EH (eds): *The pathophysiology of pneumoperitoneum*. New York: Springer-Verlag, 1998: 7-17.
8. HULKA JF, REICH H: *Textbook of laparoscopy* (2nd ed). Philadelphia, PA: WB Saunders Co, 1985: 85-102.

Acknowledgements

The author would like to thank Hans J. Lunemann, KARL STORZ Endoscopy, Tuttlingen, Germany for his generous technical and equipment support; Dr. Christopher Chamness, KARL STORZ Veterinary Endoscopy, America for his support and advice; Dr. Michael Taylor, Ontario Veterinary College for his endophotography; and the dedicated husbandry staff at the Monterey Bay Aquarium for their professionalism and efforts in maintaining such incredible creatures for this project.

**Recommended Endoscopes and Instruments
Video Documentation Systems and Accessories
for Endoscopy in Birds, Reptiles, Amphibians and Fish**

Extracts from the following catalog:

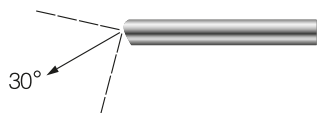
**VETERINARY ENDOSCOPY
– SMALL ANIMALS –**

including section:

**TELEPRESENCE – IMAGING SYSTEMS
Accessories for Illumination, Documentation and Data Storage**

HOPKINS® Telescope

Standard Telescope, diameter 4 mm, length 18 cm
Recommended for universal use



64230 BWA **HOPKINS® Wide Angle Forward-Oblique Telescope 30°, enlarged view**, diameter 4 mm, length 18 cm, **autoclavable**, fiber optic light transmission incorporated, color code: red

Trocar

for use with HOPKINS® Telescope 64029 BA and Sheath 64018 US



62117 GK **Trocar**, size 3.9 mm, color code: red, including:

Conical obturator

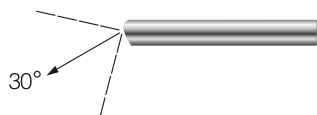
Trocar canula with outer thread, length 5 cm, with LUER-Lock connector for insufflation

Silicon valve

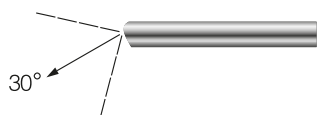
Slender HOPKINS® Telescopes, 2.7 mm

Short version: length 11 cm – for examination only

Long version: length 18 cm – for single puncture examination and diagnostic biopsy sampling



67208 BA **HOPKINS® Forward-Oblique Telescope 30°**, diameter 2.7 mm, length 11 cm, **autoclavable**, fiber optic light transmission incorporated, color code: red



64029 BA **HOPKINS® Forward-Oblique Telescope 30°, enlarged view**, diameter 2.7 mm, length 18 cm, **autoclavable**, fiber optic light transmission incorporated, color code: red

Operating Sheath 67065 CV see page 79

It is recommended to check the suitability of the product for the intended procedure prior to use.

Examination and Protection Sheath

for use with long version slender HOPKINS® Telescope 64029 BA



64018 US **Protection and Examination Sheath**, diameter 3.5 mm, working length 17 cm

Trocar, size 3.5 mm

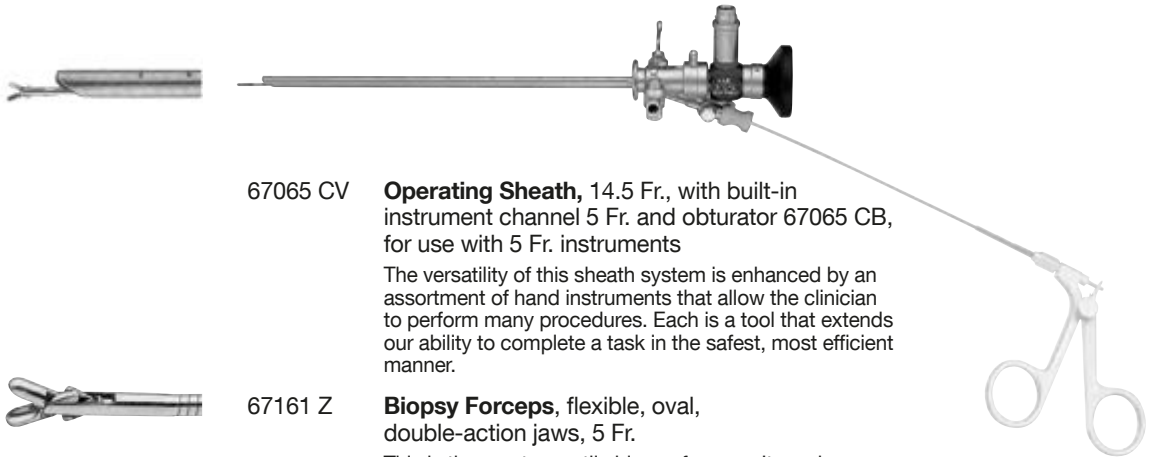
for use with HOPKINS® Telescopes 67208 BA and 64029 BA



62114 GK **Trocar**, size 3.5 mm including:
Trocar with pyramidal tip,
Trocar cannula with outer thread, length 5 cm, with Luer-lock connector for insufflation
Silicone leaflet valve

Operating Sheath, 14.5 Fr.

for use with HOPKINS® Telescope 64029 BA



67065 CV **Operating Sheath**, 14.5 Fr., with built-in instrument channel 5 Fr. and obturator 67065 CB, for use with 5 Fr. instruments

The versatility of this sheath system is enhanced by an assortment of hand instruments that allow the clinician to perform many procedures. Each is a tool that extends our ability to complete a task in the safest, most efficient manner.



67161 Z **Biopsy Forceps**, flexible, oval, double-action jaws, 5 Fr.

This is the most versatile biopsy forceps. It can be employed in most tissues and collects a deeper, longitudinal sample compared to the round cup. Also useful for sampling exudate and debris.

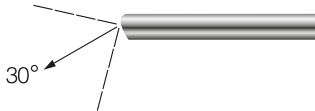


67161 T **Grasping Forceps**, flexible, double-action jaws, oval, 5 Fr.

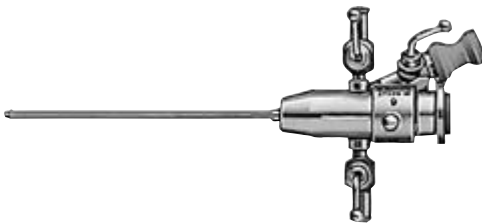
This is the standard forceps and has large serrations. Particularly useful for grasping medium to large objects and removing exudate or debris.

Slender HOPKINS® Telescope and Operating Sheath

Diameter 1.9 mm, length 10 cm



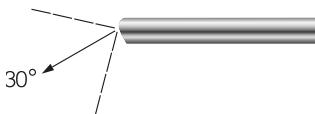
64301 BA **HOPKINS® Forward-Oblique Telescope 30°**, diameter 1.9 mm, length 10 cm, **autoclavable**, fiber optic light transmission incorporated, color code: red



61029 D **Examination Sheath, 9 Fr.**, with obturator 61029 DO and instrument channel 3 Fr., color code: red

Operating Telescope, 9.5 Fr.

for use with instruments up to 3 Fr.



67030 BA **Operating Telescope with Forward-Oblique Telescope 30°**, 9.5 Fr., **autoclavable**, fiber optic light transmission incorporated, instrument channel 3 Fr. and 2 LUER-Lock cones, color code: red



61071 TJ **Grasping Forceps**, for removing foreign bodies, double-action jaws, flexible, 3 Fr., length 28 cm



61071 ZJ **Biopsy Forceps**, double-action jaws, flexible, 3 Fr., length 28 cm



61770 AA **Ball Electrode**, 3 Fr., length 53 cm

Additional Instruments

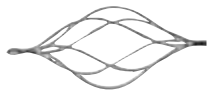
for use with Examination Sheath, 14.5 Fr.



62501 EK

Scissors, semi-rigid, single action jaws, 4 Fr., length 34 cm

The scissors are an essential part of the operating system. Air sac, peritoneal and pleural membranes can be easily incised.



67023 VK

Stone Basket, flexible, 5 Fr., length 60 cm

including:

3-ring Handle**Wire Basket****Coil**Some smooth or rounded objects can **only** be grasped by the use of a retrieval basket such as this.

67772 A

Needle Electrode, 5 Fr.

The needle can be energized using a high frequency generator for incision and coagulation of structures.



67161 M

Measurement instrument, flexible, diameter 5 Fr., length 40 cm, scale in mm

67071 X

Injection/Aspiration Needle System, 5 Fr., with outer tube, length 31 cm

The needle can be used for fluid sampling, injection, or incision of air sacs.



67159 L

High Frequency Snare, 5 Fr.

This instrument can be used for retrieval of foreign bodies, or castration in birds and reptiles when connected to a high frequency generator.

For Double Puncture Technique:

69133

Biopsy Forceps, with 3 mm oval cupped jaws, sheath diameter 1.5 mm, working length 14 cm

69117 Z

Biopsy Forceps, round cupped jaws, diameter 1.7 mm, working length 15 cm

This forceps is the same as the oval but has a round, shallow cup suited for collecting smaller samples.

CO₂ ENDO-ARTHROFLATOR™ -VET

Recommended System Configuration

Special Features:

- One unit with laparoscopy mode and arthroscopy mode
- High operating safety
- Easy to use
- Continuously adjustable insufflation pressure
- Visual and acoustic alarm signals in the event of patient overpressure
- Fully automatic, electronically controlled gas refill (e.g. in case of gas loss when changing instruments)



62 4325 20

62 4325 01 CO₂ ENDO-ARTHROFLATOR™ -VET

including:

CO₂ ENDO-ARTHROFLATOR™ -VET, power supply 100 – 240 VAC, 50/60 Hz

Mains Cord

Mains Cord, US-version

Silicone Tubing Set, sterilizable

Universal Wrench

mtp* **CO₂/N₂O Gas Filter**, sterile, for single use, package of 10

Specifications:

Operating Mode	- ARTHRO mode - LAPARO mode
Gas Flow	- 0-20 l/min - 0-20 l/min
Pressure	- 50-100 mmHg (6650 Pa-13332 Pa) - 0-15 mmHg (1999 Pa)
Gas	CO ₂
Measuring/Control System	electronic

Parameter Display	- Insufflation Pressure - Intraabdominal Press. (mmHg): 0-100 (13.3kPa) - Gas Flow (l/min): 0-20 - Gas Consumption (l): 0-999
Power Supply	100-240 VAC, 50/60 Hz
Dimensions, w x h x d	305 x 112 x 234 mm
Weight	5.5 kg
Certified to	IEC 601-1, CE

Optional Accessories:

- 20 4000 21 **High Pressure Tube CO₂**, American connection/German connection, length 55 cm
- 20 4000 27 **Same**, length 102 cm
- 20 4000 22 **High Pressure Tube CO₂**, American connection/Pin-Index Connection, length 55 cm
- 20 4000 28 **Same**, length 102 cm
- 20 4002 22 **High Pressure Tube CO₂**, American connection/ISO connection, length 102 cm
- 26 4000 90 **CO₂ Bottle**, empty, with German connection
- 26 4000 92 **Same**, filled, with German connection
- 26 4000 91 **CO₂ Bottle**, empty, with Pin-Index connection
- 26 4000 93 **Same**, filled, with Pin-Index connection
- 20 4004 21 **Low Pressure Tube**, for the central CO₂ gas supply, length 150 cm
- 20 4004 23 **Same**, length 100 cm
- 20 4000 26 **Same**, length 300 cm
- 20 4004 25 **Same**, length 600 cm

mtp* **Tubing Set with CO₂/N₂O Gas Filter**, for single use, sterile, package of 10



Fiber Optic Light Cables for Cold Light Fountains



- 69495 NL **Fiber Optic Light Cable,**
with straight connector, diameter 3.5 mm,
length 180 cm
- 69495 NA **Same,** diameter 3.5 mm, length 230 cm
- 69495 NB **Same,** diameter 4.8 mm, length 180 cm

Cold Light Fountain VETERINARY with built-in insufflation pump



- 69 111001 **Cold Light Fountain VETERINARY,**
with integrated insufflation pump,
power supply: 230 VAC, 50/60 Hz
including:
- 103 **Mains Cord**
Spare Lamp, 150 watt, 15 volt


Video Documentation Cold Light Fountain XENON NOVA® 175



- 69131501 **Cold Light Fountain XENON NOVA® 175**
lamp type: 175 W XENON lamp,
power supply: 100 – 125/220 – 240 VAC,
50/60 Hz
including:
- Cold Light Fountain XENON NOVA® 175**
Mains Cord
Spare Lamp, 175 watt, 15 volt

Veterinary Video Camera III

Single-Chip Video Camera – Color Systems PAL, NTSC



692360 01 **Veterinary Video Camera III**, color system **PAL**, single-chip technology, power supply 100 – 240 VAC, 50/60 Hz, **with** C-mount lens **20200043**, f = 38 mm, set, ready for use

692361 01 **Same**, color system **NTSC**

Please note:

The complete camera head can be disinfected by soaking in a suitable solution or sterilized in gas. The use of a sterile cover is recommended.

Accessories

for KARL STORZ Camera Systems – Color Systems PAL, NTSC

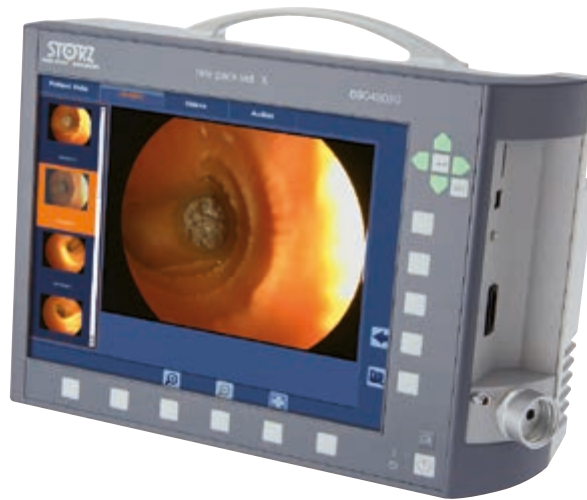

69275 N **Color Monitor 17", LCD**, NeovoX-17P, desktop version, color systems **PAL/NTSC**, max. resolution 1280 x 1024, screen diagonal 17", 1x S-Video in, 1x DVI-D, VGA input, power supply 100–240 V

69275 N

TELE PACK VET X LED

The Complete Mobile Endoscopic Video and Documentation System



RP100S1 **TELE PACK VET X LED**, endoscopic video unit for use with all KARL STORZ TELECAM one-chip camera heads, veterinary video camera heads and video endoscopes, with integrated insufflation pump, incl. LED light source similar to Xenon technology, with integrated digital Image Processing Module, 15" LCD TFT monitor with LED backlight, USB/SD memory module, color systems PAL/NTSC, power supply 100 - 240 VAC, 50/60 H, including:

KARL STORZ USB Flash Drive, 8 GB

Mains Cord

Mains Cord, US plug

Case

RP100S2 **TELECAM one-chip camera heads**, veterinary video camera heads and video endoscopes, with integrated insufflation pump, incl. LED light source similar to Xenon technology, with integrated digital Image Processing Module, 15" LCD TFT monitor with LED backlight, USB/SD memory module, color systems PAL/NTSC, power supply 100 - 240 VAC, 50/60 Hz including:

KARL STORZ USB Flash Drive, 8 GB

Mains Cord

Mains Cord, US plug

Optional Accessories

20 0141 30 **One-Pedal Footswitch**, two stage

20 0143 30 **Two-Pedal Footswitch**, one stage

495 KS **Adaptor**, for standard KARL STORZ fiber optic light cable (not 495 NCS)

20 0402 40DE **Keyboard**, with German character set

20 0402 40ES **Keyboard**, with Spanish character set

20 0402 40FR **Keyboard**, with French character set

20 0402 40IT **Keyboard**, with Italian character set

20 0402 40PT **Keyboard**, with Portuguese character set

20 0402 40RU **Keyboard**, with Russian character set

20 0402 40US **Keyboard**, with US-English character set

Notes:

